



# Overt Bleeding from Small Bowel Ulcers due to Microscopic Polyangiitis

João Correia<sup>1\*</sup>, Catarina Gomes<sup>1</sup>, Ana Ponte<sup>1</sup>, David João<sup>1</sup>, Teresa Freitas<sup>1</sup>

<sup>1</sup>Gastroenterology Department, Centro Hospitalar Vila Nova de Gaia/Espinho, Vila Nova de Gaia, Portugal

## Please cite this paper as:

Correia J, Gomes C, Ponte A, João D, Freitas T. Overt bleeding from small bowel ulcers due to microscopic polyangiitis. *Middle East J Dig Dis* 2022;14(4):488-490. doi: 10.34172/mejdd.2022.312.

## Clinical Challenge

Microscopic polyangiitis is a pauci-immune, antineutrophil cytoplasmic antibody (ANCA)-associated vasculitis that affects small blood vessels.<sup>1</sup> Myeloperoxidase (MPO)-ANCA stimulates neutrophil-induced cytotoxicity toward endothelial cells, leading to vessel wall inflammation, obliteration, and damage.<sup>1</sup> It typically involves the lungs and kidneys, with rare potential to involve the gastrointestinal tract, especially presenting with bleeding from small bowel lesions.<sup>2</sup>

The authors present a case of a 63-year-old woman who was admitted to the emergency room after syncope and a 4-day of hematochezia. She had a medical history of rapidly progressive glomerulonephritis due to MPO-ANCA associated vasculitis since 2 years earlier. In the previous year, she was hospitalized due to a pulmonary-renal syndrome related to the vasculitis process. Apart from acetylsalicylic acid, the patient was not taking any other medication. In the current admission, she did not reveal respiratory symptoms. Laboratory studies revealed a hemoglobin level of 7.2 g/dL. Colonoscopy showed dark blood in the terminal ileum. An esophagogastroduodenoscopy was performed with no significant findings. Capsule endoscopy detected fresh blood in the distal ileum without identifying the underlying lesion. The patient underwent retrograde single-balloon enteroscopy, identifying segmental involvement with areas of congestive and ulcerated mucosa in the distal ileum (Figure 1). Histological examination confirmed an ischemic process associated with vasculitis in the small bowel (Figure 2). Intermittent pulses of cyclophosphamide and intravenous methylprednisolone were instituted. After 20 days of treatment, she was asymptomatic without new episodes of evident blood loss and was discharged with an oral prednisolone taper scheme.

The majority of small bowel ulcers are due to inflammatory bowel disease or non-steroidal anti-inflammatory drug consumption.<sup>3</sup> However, there are multiple differential diagnoses that must be considered. Our case elucidates the importance of an adequate anamnesis and work-up assessment (endoscopy and histology) in the final diagnosis of overt obscure gastrointestinal bleeding.

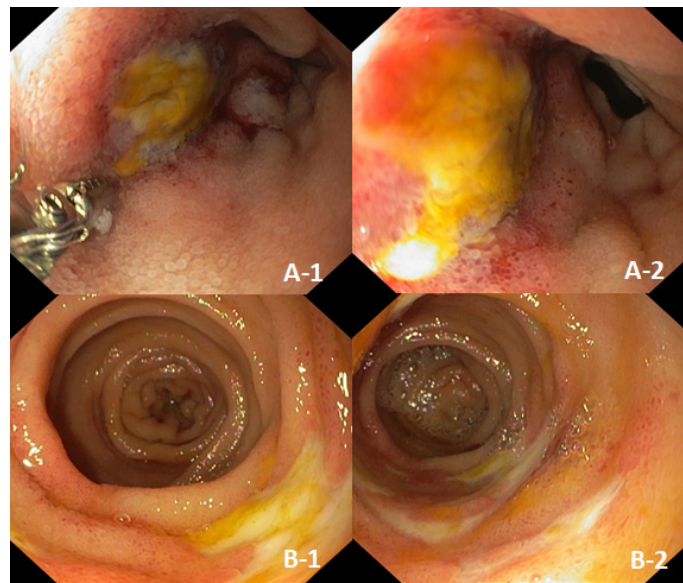
## \* Corresponding Author:

João Correia  
R. Conceição Fernandes S/N  
Tel: +351 227 865 100  
Fax: +351 227868369  
Email: joaopaulo\_laranjeira@hotmail.com

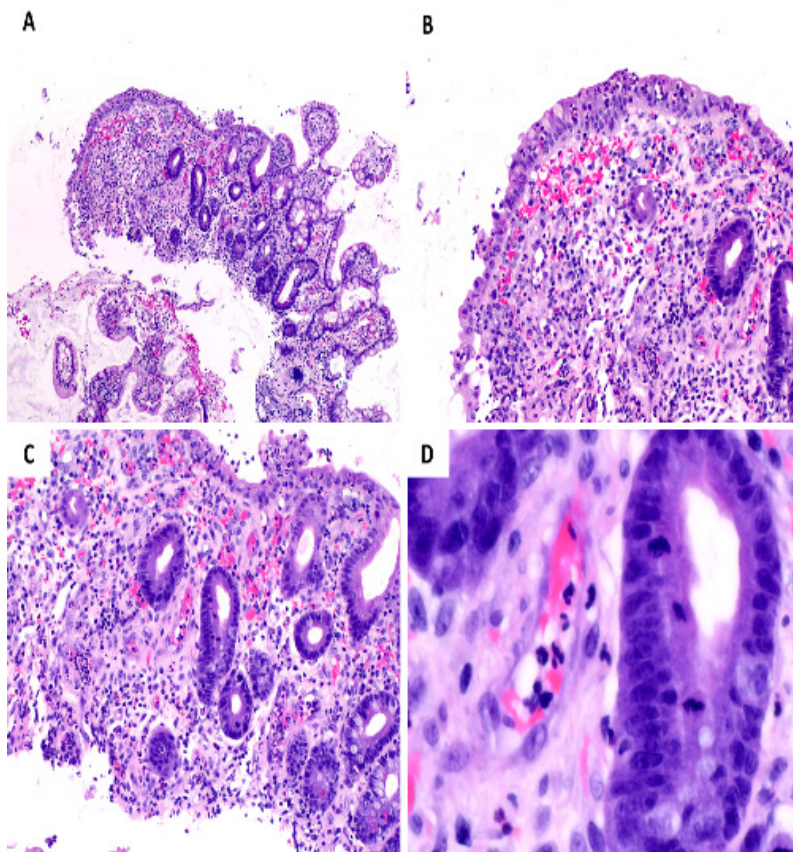
Received : 02 May 2022  
Accepted : 04 Sep. 2022  
Published: 30 Oct. 2022



© 2022 The Author(s). This work is published by Middle East Journal of Digestive Diseases as an open access article distributed under the terms of the Creative Commons Attribution License (<https://creativecommons.org/licenses/by-nc/4.0/>). Non-commercial uses of the work are permitted, provided the original work is properly cited.



**Figure 1.** Single-balloon enteroscopy findings. A(1-2): Terminal ileum ulcer; B(1-2): Segmental area with 5 cm extension of congestive and ulcerated mucosa



**Figure 2.** Histopathological findings of small bowel biopsy. On low power (H&E, 40X), evidence of erosion, ulceration, fibrosis, granulation tissue, and reactive glandular epithelium could be found (A). These features are better displayed on medium power (H&E, 100X) (B). Small-vessel vasculitis was striking (H&E, 100X) (C), with an inflammatory infiltrate mainly comprised of neutrophils permeating the capillaries (H&E, 400X) (D).

#### Conflict of Interest

The authors have no conflicts of interest to declare.

#### Ethical Approval

At our center, we obtain a procedure's consent, and patients also consent to future studies that might develop with data obtained from the procedure.

#### Funding

There was no funding involved.

#### References

1. Katikineni VS, Kant S, Gapud EJ, Antiochos B, Manno RL, Phillips M, et al. Uncommon presentations in ANCA vasculitis: clinical characteristics and outcomes. *Clin Rheumatol* 2019;38(8):2195-9. doi: [10.1007/s10067-019-04568-4](https://doi.org/10.1007/s10067-019-04568-4)
2. Segraves JM, Iyer VN. Microscopic polyangiitis: atypical presentation with extensive small bowel necrosis, diffuse alveolar hemorrhage, and renal failure. *Respir Med Case Rep* 2017;21:12-5. doi: [10.1016/j.rmcr.2017.03.001](https://doi.org/10.1016/j.rmcr.2017.03.001)
3. Keuchel M, Kurniawan N, Baltes P. Small bowel ulcers: when is it not inflammatory bowel disease? *Curr Opin Gastroenterol* 2019;35(3):213-22. doi: [10.1097/mog.0000000000000522](https://doi.org/10.1097/mog.0000000000000522)