



## Laparoscopy-Assisted Endoscopic Retrograde Cholangiopancreatography: New Insight in Management of Iatrogenic Bile Duct Injury

Mohamed H Emara<sup>1\*</sup>, Hassan E. Elbatae<sup>1</sup>, Reda F Ali<sup>2</sup>, Mohammed H. Ahmed<sup>1</sup>, Mohamed Said Radwan<sup>1</sup>, Abdulhamid Elhawary<sup>3</sup>

<sup>1</sup>Hepatology, Gastroenterology, and Infectious Diseases Department, Faculty of Medicine, Kafrelsheikh University, Kafrelsheikh, Egypt

<sup>2</sup>Surgery Department, Faculty of Medicine, Kafrelsheikh University, Kafrelsheikh, Egypt

<sup>3</sup>Anaesthesia Department, Faculty of Medicine, Kafrelsheikh University, Kafrelsheikh, Egypt

### Abstract

Bile duct injury (BDI) is a severe and sometimes life-threatening complication of cholecystectomy. Several series have described a 0.5% to 0.6% incidence of BDI during laparoscopic cholecystectomy. We received an emergency call from the operating theater by the surgery team to assess an iatrogenic BDI in a 58-year-old man with cirrhosis who presented for laparoscopic cholecystectomy. After many trials by endoscopic retrograde cholangiopancreatography (ERCP) the guide wire passed to the peritoneal cavity and failed to pass proximally. Laparoscopy resumed, and the surgeon tried to pass the flexible guide wire proximally unsuccessfully. Then, a decision to hold the sphincterotomy by laparoscopy and passing it proximally in harmony with ERCP was taken, which was successful. A regular ERCP with 10F plastic stent insertion was carried out, and the perforation was secured by the inserted stent without any further surgical intervention. Laparoscopy-assisted ERCP may give new insights into the immediate repair of iatrogenic bile duct injuries.

### Keywords:

Laparoscopy, ERCP, CBD, Iatrogenic, Sphincterotomy

### Please cite this paper as:

Emara MH, Elbatae HE, Ali RF, Ahmed MH, Radwan MS, Elhawary A. Laparoscopy-assisted endoscopic retrograde cholangiopancreatography: new insight in management of iatrogenic bile duct injury. *Middle East J Dig Dis* 2022;14(4):473-477. doi: 10.34172/mejdd.2022.309.

### \* Corresponding Author:

Mohamed H Emara, MD  
Hepatology, Gastroenterology, and Infectious Diseases Department, Faculty of Medicine, Kafrelsheikh University, Kafrelsheikh, 33516, Egypt.  
Tel: +201002724482  
Fax: +20473611224  
Emails: emara\_20007@yahoo.com, Mohamed\_emara@med.kfs.edu.eg

Received : 30 Dec. 2021  
Accepted : 02 Sep. 2022  
Published: 30 Oct. 2022

### Introduction

Bile duct injury (BDI) is not infrequently seen during hepatobiliary surgery, particularly after liver transplantation and cholecystectomy. BDI is severe and sometimes is a potentially life-threatening complication of cholecystectomy, either laparoscopic or open. Several series have described a 0.5% to 0.6% incidence of BDI during laparoscopic cholecystectomy.<sup>1</sup> However, the rate of clinically relevant bile leaks after conventional open cholecystectomy is low with ranges between 0.1% and 0.5%.<sup>2</sup>

The best diagnostic method of BDI is witnessing the injury, which is achievable only in 30% of cases during surgery. However, the extent of the injury may require certain diagnostic modalities. It seems that magnetic resonance cholangiopancreatography is the ideal diagnostic test when BDI is suspected following cholecystectomy.<sup>3</sup>

Regarding repair of bile duct injuries following cholecystectomy,



© 2022 The Author(s). This work is published by Middle East Journal of Digestive Diseases as an open access article distributed under the terms of the Creative Commons Attribution License (<https://creativecommons.org/licenses/by-nc/4.0/>). Non-commercial uses of the work are permitted, provided the original work is properly cited.

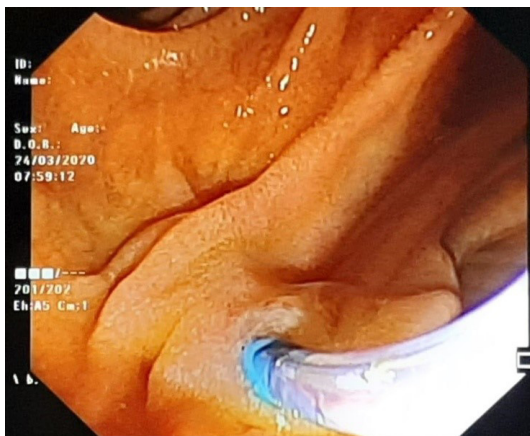one study showed that early (2 weeks) surgical interventions were comparable to late (12 weeks) surgical interventions.<sup>4</sup> However, when endoscopic retrograde cholangiopancreatography (ERCP) was introduced, gathered data showed that endoscopic therapy was safe and effective in the management of postoperative bile duct leak.<sup>5</sup> ERCP was used mainly to treat late (beyond one week) diagnosed biliary injuries when most of the patients present with bile leakage or obstructive jaundice, while injuries diagnosed intraoperatively were treated surgically either by repair, biliary approximation, or through jejunal anastomosis.<sup>5,6</sup> The data about early endoscopic intervention is scarce.

Although surgical repair is the standard of care in the immediate repair of iatrogenic bile duct injuries, we present here – for the first time – a complete report of laparoscopy-assisted ERCP as rescue management of iatrogenic BDI during laparoscopic cholecystectomy, representing a new insight in this area.

### Case Report

We received an emergency call from the operating theater by the surgery team to assess an observed iatrogenic BDI in a 58-year-old man with cirrhosis who presented for laparoscopic cholecystectomy. The ERCP unit was moved to the OR.

**Step 1:** Initially, by ERCP, cannulation of the normal-shaped papilla was achieved in the left lateral position (Figure 1).



**Figure 1.** Endoscopic view for papillary cannulation with the sphincterotome. Cannulation of the normal papilla (type 1) was achieved with a triple lumen sphincterotome in the left lateral position

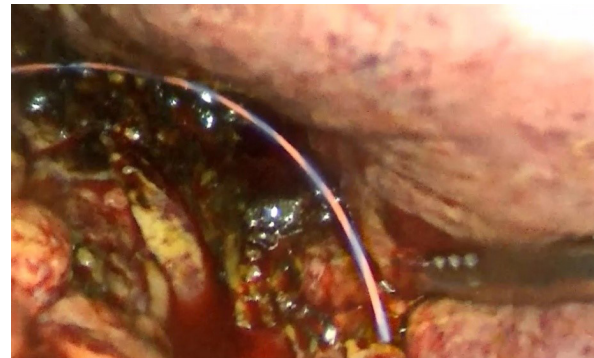
After many trials by ERCP, the guide wire passed to the peritoneal cavity and failed to pass proximally (Figure 2) in spite of many trials and using guide wires of variable diameters.

**Step 2:** Laparoscopy resumed, and the patient was brought to the supine position. The surgeon tried to pass the flexible guide wire proximally unsuccessfully (Figure 3).

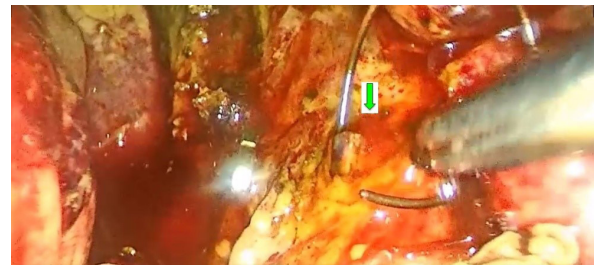
A decision to hold the sphincterotome by laparoscopy and passing it proximally in harmony with ERCP was taken and was successful (Figure 4).

After the sphincterotome passed proximally, the surgeon, through the laparoscopy, supported the sphincterotome until deep cannulation of the biliary system was secured (Figure 5).

**Step 3:** After deep biliary cannulation, a complete ERCP was performed, and a plastic stent 10cm/10F was then inserted successfully.



**Figure 2.** Laparoscopy picture showing the guide wire in the peritoneal cavity. Through the bile tear, the 0.035 mm guide wire passed to the peritoneal cavity and failed to pass proximally



**Figure 3.** Laparoscopy picture showing the guide wire held by the surgeon. The surgeon holds the 0.035 mm guidewire and tries to pass it through the CHD defect (arrow). The arrow points to the biliary tear. Notice also the tip of the sphincterotome appear through the tear

## Treatment

### Intraoperative

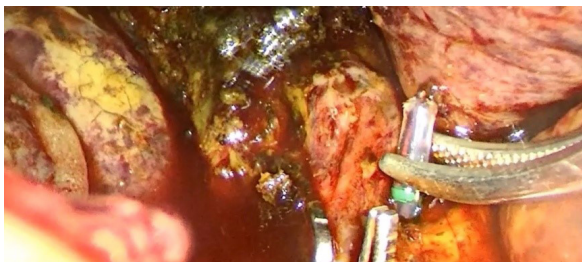
The perforation of the bile duct was secured by the plastic stent insertion without applying any clips or sutures to the bile duct, and no more bile was seen flowing from the perforation site.

### Postoperative

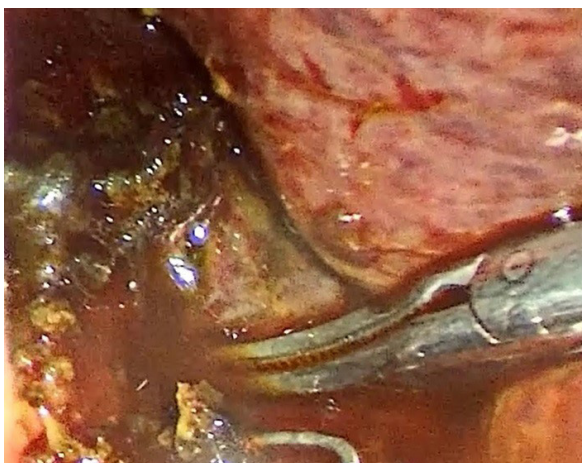
Follow-up for days showed no bile in the surgical drains, and after 3 days, the drains were dry and removed. Follow-up lab showed normal bilirubin level (1.3 total 0.5 direct mg/dL), normal liver enzymes, and normal complete blood count.

### Three months follow up

Three months later, an ERCP was performed, the inserted stent was removed, and the cholangiogram



**Figure 4.** Laparoscopy picture showing the sphincterotome held by the surgeon. The surgeon holds the sphincterotome that emerged from the tear and begins to pass it proximally. Notice the cirrhotic liver opposite the tip of the sphincterotome



**Figure 5.** Laparoscopy picture showing the surgeon supporting the bile duct. The surgeon supports the sphincterotome after passing it successfully proximally

showed short segment common hepatic duct (CHD) (Bismuth type III), as shown in [Figure 6](#).

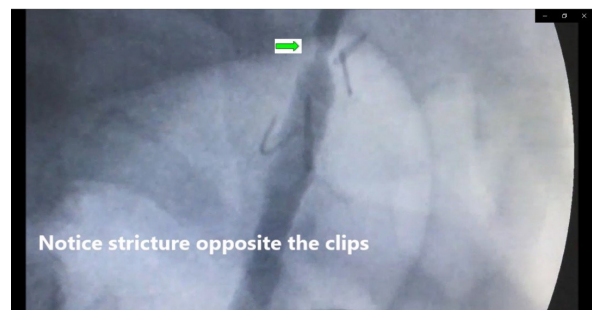
This stricture was treated by double plastic stent insertion for a further 3 months with a favorable outcome.

## Discussion

The incidence of BDI is widely variable in the literature and ranges from 0.1% to 3%.<sup>1,2,6</sup> It seems that this incidence will not be going to drop because the maneuver is increasingly popular, more and more being performed. Moreover, more junior surgeons are being trained, and furthermore also, problematic patients e.g. patients with deranged anatomy, cirrhosis etc. are being operated.

The case discussed here is interesting from different angles. First, the introduction of this hybrid technique in the management of bile duct injurers. In fact, we searched the literature for a combination of ERCP with laparoscopy, and as expected, we found this technique is used mainly for patients with deranged gastric anatomy after gastric Roux in Y bypass for either gastric outlet obstruction or following bariatric surgery with variable degrees of success.<sup>7,8</sup> But, we did not find a description for this maneuver in the emergency management of iatrogenic biliary injuries because the current guidelines recommend immediate surgical intervention.

In fact, intraoperative ERCP was used for the management of common bile duct (CBD) stones in patients with cholecystitis when patients are scheduled to have both cholecystectomy and CBD stone extraction in the same setting, avoiding the classically described cholecystectomy and CBD exploration.<sup>9</sup>



**Figure 6.** Cholangiogram, 3 months after surgery. Cholangiogram during the second ERCP showing a short segment stricture of the bile duct (arrow)

Intraoperative ERCP has the advantage of being a single-stage treatment and has a significant success rate, an easy learning curve, low morbidity involving a shorter hospital stay, and lower costs than the two-stage treatments (postoperative and preoperative ERCP). Intraoperative ERCP is also a good salvage treatment when preoperative ERCP fails or when total laparoscopic management also fails.<sup>10</sup>

The second interesting point is the rapid response to the emergency call from our surgical team. This message should be delivered to our junior endoscopists and surgeons. Working in a team and immediate response to calls is not only an ethical amendment but rather a success point for both patient outcomes and hospital reputations. Unfortunately, in developing countries, we lack a great proportion of this teamwork success.

Third, practicing ERCP during this emergency situation carries a number of challenges. In this case, the CBD defect was large enough to prevent the passage of the guide wire proximally, we changed different guide wires with different diameters and stiffness, and without the help of the laparoscopy, we would have failed. One more is operating for laparoscopy and ERCP at the same time point, and this is by itself a challenge from two points; the supine position of the patient and air insufflations. For the supine position, which is the preferred position in laparoscopy, the air is insufflated, and we noticed that maintaining a good view of the papilla was difficult and even we lost facing the papilla several times. On the other side, during ERCP, we usually operate in the left lateral or prone positions, which is impossible for laparoscopy, moreover, air insufflation was annoying to the surgeon, gastric distension was particularly annoying, and we had to suck air several times as per surgeon needs. One more technical point, what makes the sphincterotome successfully pass proximally while the guidewire fails? Simply the answer is related to the flexibility of both. Sphincterotome is rigid, while the guidewire is flexible, easily bent, and fails to have a solid texture

Fourth, the major role played by the surgeon. Most of the described laparoscopy-assisted ERCP techniques are dependent mainly on the endoscopist, while the role of the surgeon is limited to gaining access of the scope through the abdominal cavity and gastric wall

puncture.<sup>7,8</sup> Here, the situation is rather different. The surgeon played a peculiar, interesting, and very helpful task, not only the deep cannulation but also securing the cannulation through the support exerted on the sphincterotome after successfully passing it proximally.

Fifth, the new hypothesis tested here is that laparoscopy-assisted ERCP may give new insights into the immediate repair of iatrogenic bile duct injuries, although the surgical repair is the standard of care in the immediate repair of iatrogenic bile duct injuries.

In conclusion, the combination of ERCP and laparoscopy is feasible for treating acute iatrogenic bile duct injuries in spite of different technical difficulties. We did not violate the well-known fact that early surgical repair of iatrogenic bile duct injuries is the currently recommended line of management,<sup>11</sup> but we would favor new insights in the introduction of ERCP in immediate biliary repair. This maneuver emphasized the cooperation between the laparoscopic surgeon and the endoscopist in managing acutely injured CBD.

#### Acknowledgments

The authors would thank all colleagues who helped to document this case.

#### Author Contributions

ME, AE and RF: treated the case initially and performed the combined endoscopy and laparoscopy. MH and ME followed up the patient at 3 months. ME and HE searched the literature and designed the concept of the study. ME and MH wrote the article. RF and MR revised the figures. All authors revised the draft and approved the final manuscript.

#### Conflict of Interest

None.

#### Consent for Publication

Informed consent was obtained from the patient for publication of this report.

#### Data Availability

The authors declare that data supporting the findings of this study are available within the article.

#### Funding

None.

#### References

1. Manouras A, Pararas N, Antonakis P, Lagoudiannakis

- EE, Papageorgiou G, Dalianoudis IG, et al. Management of major bile duct injury after laparoscopic cholecystectomy: a case report. *J Med Case Rep* 2009;3:44. doi: [10.1186/1752-1947-3-44](https://doi.org/10.1186/1752-1947-3-44)
2. Flum DR, Cheadle A, Prael C, Dellinger EP, Chan L. Bile duct injury during cholecystectomy and survival in medicare beneficiaries. *JAMA* 2003;290(16):2168-73. doi: [10.1001/jama.290.16.2168](https://doi.org/10.1001/jama.290.16.2168)
  3. Abou El-Ella KM, Mohamed ON, El-Sebayel MI, Al-Semayer SA, Al Mofleh IA. Management of postlaparoscopic cholecystectomy major bile duct injury: comparison of MRCP with conventional methods. *Saudi J Gastroenterol* 2004;10(1):8-15.
  4. Felekouras E, Petrou A, Neofytou K, Moris D, Dimitrokallis N, Bramis K, et al. Early or delayed intervention for bile duct injuries following laparoscopic cholecystectomy? A dilemma looking for an answer. *Gastroenterol Res Pract* 2015;2015:104235. doi: [10.1155/2015/104235](https://doi.org/10.1155/2015/104235)
  5. Abdel-Raouf A, Hamdy E, El-Hanafy E, El-Ebidy G. Endoscopic management of postoperative bile duct injuries: a single center experience. *Saudi J Gastroenterol* 2010;16(1):19-24. doi: [10.4103/1319-3767.58763](https://doi.org/10.4103/1319-3767.58763)
  6. Yehia AMA. Management of cholecystectomy-induced biliary injuries at Zagazig University Hospital. *Egypt J Surg* 2018;37(2):223-9. doi: [10.4103/ejs.ejs\\_9\\_18](https://doi.org/10.4103/ejs.ejs_9_18)
  7. Habenicht Yancey K, McCormack LK, McNatt SS, Powell MS, Fernandez AZ, Westcott CJ. Laparoscopic-assisted transgastric ERCP: a single-institution experience. *J Obes* 2018;2018:8275965. doi: [10.1155/2018/8275965](https://doi.org/10.1155/2018/8275965)
  8. Snauwaert C, Laukens P, Dillemans B, Himpens J, De Looze D, Deprez PH, et al. Laparoscopy-assisted transgastric endoscopic retrograde cholangiopancreatography in bariatric Roux-en-Y gastric bypass patients. *Endosc Int Open* 2015;3(5):E458-63. doi: [10.1055/s-0034-1392108](https://doi.org/10.1055/s-0034-1392108)
  9. Elgeidie A, Atif E, Elebidy G. Intraoperative ERCP for management of cholecystocholedocholithiasis. *Surg Endosc* 2017;31(2):809-16. doi: [10.1007/s00464-016-5036-1](https://doi.org/10.1007/s00464-016-5036-1)
  10. Rábago LR, Ortega A, Chico I, Collado D, Olivares A, Castro JL, et al. Intraoperative ERCP: what role does it have in the era of laparoscopic cholecystectomy? *World J Gastrointest Endosc* 2011;3(12):248-55. doi: [10.4253/wjge.v3.i12.248](https://doi.org/10.4253/wjge.v3.i12.248)
  11. Battal M, Yazici P, Bostanci O, Karatepe O. Early surgical repair of bile duct injuries following laparoscopic cholecystectomy: the sooner the better. *Surg J (N Y)* 2019;5(4):e154-e8. doi: [10.1055/s-0039-1697633](https://doi.org/10.1055/s-0039-1697633)