



Type II Enteropathy-Associated T-cell Lymphoma: A Rare Report from Iran

Neda Nozari ^{1,2*}

1. Researcher, Digestive Disease Research Institute, Shariati Hospital, Tehran University of Medical Sciences, Tehran, Iran
2. Shahid Rajai Hospital, Alborz University of Medical Sciences, Karaj, Iran

ABSTRACT

Type II enteropathy-associated T-cell lymphoma (EATL) is a rare disease that is reported from Asia, especially from Taiwan. In this paper, we present a patient from Iran (Arab) with Type II EATL whose disease was not associated with celiac disease or Epstein-Barr virus (EBV) infection. The patient died due to intestinal perforation during the first chemotherapy. Type II EATL is a gastrointestinal lymphoma with poor prognosis and a high affinity for intestinal perforation. Early detection of EATL II is essential for chemotherapy prior to the onset of malnutrition symptoms.

KEYWORDS:

Non-Hodgkin lymphoma, T cell lymphoma, Intestinal perforation

Please cite this paper as:

Nozari N. Type II Enteropathy-Associated T-cell Lymphoma: A Rare Report from Iran. *Middle East J Dig Dis* 2017;9:55-57. DOI: 10.15171/mejdd.2016.52

INTRODUCTION

Enteropathy-associated T-cell lymphoma (EATL) is uncommon and composes almost 4.5% of non-Hodgkin lymphomas.¹⁻³ EATL can be associated with celiac disease.¹ It commonly occurs in the small intestine (jejunum and ileum) in the form of single or multiple lesions. Common symptoms of EATL are bowel perforation and severe abdominal pain due to intestinal obstruction.²

CASE REPORT

A 35-year-old man from Ahvaz (Arab), Iran was referred to our hospital due to chronic diarrhea and for further evaluation. He had been suffering from severe watery diarrhea from 3 months earlier. In his upper endoscopy scalloping view in duodenum had been reported and evaluation of biopsy samples was suggestive for celiac disease. Macroscopic or microscopic evidence of any disease or infection had not been seen in colonoscopy. A gluten-free diet had been started because of a clinical suspicion of celiac disease (negative serology and positive pathology) since 2 months earlier. The patient had developed severe weight loss (30 kg), fatigue, and anorexia and had no clinical response to gluten-free diet. He had been admitted in a local hospital due to severe weakness and sweating a month before. In enteroscopy scalloping view from duodenum up to ileum had been reported. Multiple small ulcers had also been reported in the jejunum and ileum. Pathological evaluation showed evidence of

*Corresponding Author:

Neda Nozari, MD
Gastroenterology Department, Mohamad
Digestive Disease Research Institute,
Shariati Hospital,
Tehran University of Medical Sciences,
Tehran, Iran
Tel: +98 21 82415000
Fax: +98 21 82415400
Email: nozari_neda@yahoo.com.

Received: 02 Sep. 2016
Accepted: 01 Dec. 2016

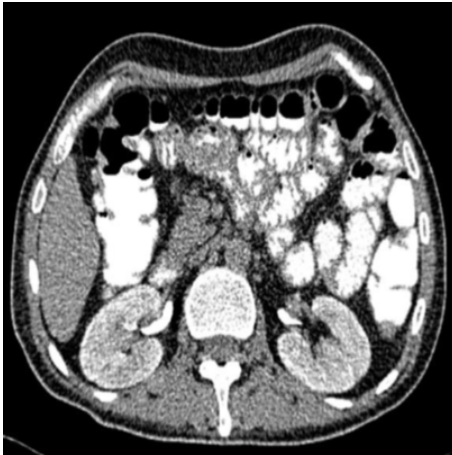

Fig.1: Intestinal wall thickening in the axial slice of abdominopelvic CT


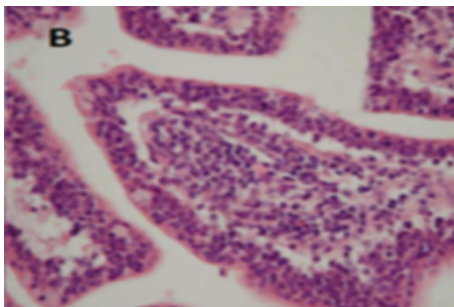
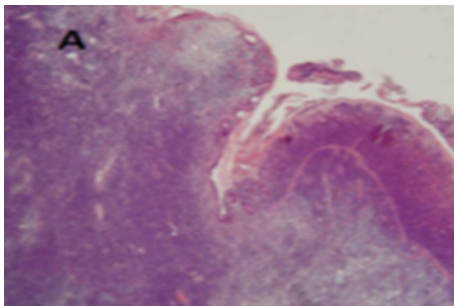


Fig.1: A. Low power image of small intestine with almost complete villus atrophy and trans-mural lymphoid infiltration B. High power image of the mucosa with intraepithelial lymphocytosis C. Positive CD3 in lymphoid infiltration.⁷

villous atrophy with intraepithelial lymphocytosis. However no evidence of intestinal infections was reported in laboratory or pathological assessments. The patient was referred to our hospital with the clinical suspicion of lymphoma and for further investigation. He was extremely cachectic and weak (BMI < 20 Kg/m²). In physical examination, he had blood pressure: 100/60 mmHg, heart rate: 96 beats/min, temperature: 37.5°C. Laboratory evaluation showed normal white blood cell and platelet counts. Serum hemoglobin level was 12 g/dL, C-reactive protein (CRP): 35 mg/dL, lactate dehydrogenase (LDH): 560 U/L, and albumin: 1/5 g/dL. The patient received supportive treatments for his severe weakness. Abdominopelvic computed tomography (CT) with intravenous and oral contrasts showed diffuse intestinal wall thickening with no evidence of obstruction or obvious mass (figure 1).

Biopsy samples of the small intestine were referred to a gastrointestinal pathologist. CD3 of the samples was positive and T cell lymphoma was considered. PCR for T cell receptor was requested and type II EATL was confirmed (figure 2).

The patient's background for lymphoma showed negative HLA DQ2 and DQ8 and also negative serology and evidence of Epstein-Barr virus (EBV) infection in tumor cells. The patient was not considered for surgery due to severe malnutrition and only chemotherapy (cyclophosphamide, hydroxyl doxorubicin, vincristine, and prednisone [CHOP regimen]) was started for him. Unfortunately, he died due to intestinal perforation and septic shock during the first chemotherapy.

DISCUSSION

EATL has two types based on genetic and pathological subtypes. Type I has 80-90% prevalence and is associated with celiac disease (usually positive HLA DQ2 and sometimes positive HLA DQ8) and phenotype CD3⁺, CD56⁻, CD8⁻. Type II has 10-20% prevalence and has no association with celiac disease (lack of HLA DQ2 or HLA DQ8) and phenotype CD3⁺, CD56⁺, CD8^{+/-}.³⁻⁷ Evidence of EBV infection is negative in tumor cells of EATL II.⁵ EATL I is mostly seen in the West and composes more than 90% of EATL,⁶ but EATL II is mostly seen in Asia, especially in Taiwan.^{2,5,6} Symptoms of mal-

nutrition and weight loss are mostly seen in type I and bowel obstruction or perforation is mostly seen in type II.^{3,7} Jejunum or ileum is involved in more than 90% of EATL II and duodenum involvement is seen rarely.² In this case, duodenum was involved in addition to jejunum and ileum. CHOP regimen is used in the treatment of T cell lymphoma,^{2-4,7} and the mean survival of patients with chemotherapy is 7 months.^{2-4,7} However, the survival of patients can be improved by autologous stem cell transplantation (ASCT) after chemotherapy (based on anthracycline).^{2-4,6} Large size of the tumor, high levels of LDH and CRP, low level of albumin, cachexia, celiac form resistant to treatment, lack of response to chemotherapy, and the impossibility of reducing the tumor size by surgery are suggested as the poor prognostic factors.^{2-4,6} Mean survival of 5 years in the EATL with celiac or type I is 60% and 0% in type II.⁴ Early detection of EATL II (before the malnutrition symptoms and disease complications) is essential for chemotherapy.⁷ In EATL II, the bowel perforation is 23% at the time of diagnosis and 17% during chemotherapy. Bowel perforation often occurs in the first chemotherapy and is often fatal. Asian studies reported high rates of bowel perforation (80%) in EATL II. Surgical intervention before chemotherapy is recommended due to the risk of bowel perforation during EATL II chemotherapy. Surgical procedures should be carefully selected to prepare the patient for chemotherapy as soon as possible.^{1,3}

CONFLICT OF INTEREST

The author declares no conflict of interest related to this work.

REFERENCES

1. Babel N, Paragi P, Chamberlain RS. Management of enteropathy-associated T-cell lymphoma: an algorithmic approach. *Case Rep Oncol* 2009;**2**:36-43. doi: 10.1159/000205183.
2. Makruasi N, Makruasi S, Trongwongsa T. Entropathy type II associated T cell non Hodgkin lymphoma: A case report. *J Hematol* 2015;**4**:144-7. doi: <http://dx.doi.org/10.14740/jh186w>.
3. Yeh FC, Gao HW, Hsu SD, Chen JH, Kao WY. Intestinal perforation complicating type II enteropathy-associated T-cell lymphoma. *J Med Sci* 2014;**34**:140-4. doi: 10.4103/1011-4564.134416.
4. Malamut G, Chandesris O, Verkarre V, Meresse B, Callens C, Macintyre E, et al. Entropathy associated T cell lymphoma in celiac disease: A large retrospective study. *Dig Liver Dis* 2013;**45**:377-84. doi: 10.1016/j.dld.2012.12.001.
5. Song MJ, Park CH, Hwang HS, Suh CH, Yoon DH, Huh J. A case of type II enteropathy associated T cell lymphoma with Epstein barr virus positivity. *Korean J Pathol* 2014;**48**:426-29. doi:10.4132/KoreanJ-Pathol.2014.48.6.426
6. Delabie J, Holte H, Vose J, Ullrich F, Jaffe ES, Savage KJ, et al. Entropathy associated T cell lymphoma: clinical and histological findings from the international peripheral T cell lymphoma project. *Blood* 2011;**118**:148-55. doi:10.1182/blood-2011-02-335216
7. Wali GN, Tyrrell HE, Collins GP, Eagleton HJ. A rare but potentially fatal cause of diarrhea and weight loss: enteropathy associated T cell lymphoma. *BMJ Case Reports* 2015. doi: 10.1136/bcr-2014-204125.