

Incidental Diagnosis of Appendiceal Abscess by Colonoscopy; A Case Report and Review of the Literature

Ramin Niknam¹, Mohammad Reza Fattahi¹, Laleh Mahmoudi^{2*}

1. Gastroenterohepatology Research Center, Shiraz University of Medical Sciences, Shiraz, Iran
2. Department of Clinical Pharmacy, School of pharmacy, Shiraz University of Medical Sciences, Shiraz, Iran

ABSTRACT

Although complicated acute appendicitis is occasionally observed in general practice, the diagnosis of appendiceal abscess by colonoscopy is unusual. We report a case of appendiceal abscess with spontaneous drainage into the lumen of colon diagnosed during colonoscopy and resolved by the time of surgery.

KEYWORDS

Appendiceal Abscess; Colonoscopy; Surgery

Please cite this paper as:

Niknam R, Fattahi MR, Mahmoudi L. Incidental Diagnosis of Appendiceal Abscess by Colonoscopy: a Case Report and Review of the Literature. *Middle East J Dig Dis* 2015;7:100-3.

INTRODUCTION

Acute appendicitis is considered as the most frequent cause of acute abdomen in young patients with a slight predominance in males.¹ Although its clinical diagnosis is simple, 20-30% of appendicitis cases are reported to be gangrenous or perforated because of delayed diagnosis, which can lead to increased morbidity and mortality.²

Additionally, up to 10% of patients especially older ones, immunocompromised patients, and pregnant women are diagnosed with atypical presentations such as appendiceal mass^{3,4} which requires long hospital admissions, intravenous antibiotics, and often needs percutaneous drainage.

Using colonoscopy for the diagnosis and treatment of asymptomatic acute appendicitis and appendiceal abscess are rare. In unusual appendicitis cases, especially in the presence of abdominal comorbidities, colonoscopy is used; although colonoscopy is not considered as the first line intervention because of complications' risk such as bleeding or perforation. Furthermore non-invasive tests such as ultrasonography and computed tomography with more sensitivity can be used.¹ We report an atypical case of appendiceal abscess, which was diagnosed during colonoscopy.

CASE REPORT

A 30-year-old man referred for evaluation to our center with epigastric pain from three days prior to his evaluation. The pain was nonspecific and colicky distributed in periumbilical region, did not radiate to any site and was unrelated to bowel movements. He had experienced

* Corresponding Author:

Laleh Mahmoudi, PhD
Department of Clinical Pharmacy, School of Pharmacy, Shiraz University of Medical Sciences, Shiraz, Iran
Tel: +98 711 2424128
Fax: +98 711 2424126
Email: Mahmoudi_r@sums.ac.ir
Received: 20 Dec. 2014
Accepted: 12 Mar. 2015

also nausea, anorexia and intermittent vomiting.

There was a history of marijuana and alcohol usage from several years ago. Upon physical examination, he was ill with restlessness. There was mild periumbilical tenderness without rebound tenderness. There was no other positive finding in physical examinations.

The patient's laboratory results upon admission showed mild leukocytosis. Other laboratory values such as hemoglobin, platelets, serum amylase, erythrocyte sedimentation rate, aspartate aminotransferase, alanine aminotransferase, alkaline phosphatase, and electrolytes were normal.

His workup on admission including; chest x-ray, abdominal x-ray, and abdominal ultrasonography were reported normal. An upper gastrointestinal endoscopy was performed after four days of admission that was normal.

Within second week after admission, because of continuing pain, colonoscopy was performed. The left and right colon appeared normal. The terminal ileum was also examined and appeared normal. The appendiceal orifice was discovered in the floor of cecum which was draining pus into the lumen (Figure 1).

Result of the biopsies of the mucosa at the base of the appendix showed mild nonspecific inflammation with some necrotic materials and staphylococcus organism. The biopsies of the mucosa at terminal ileum, left and right colon demonstrated mild nonspecific inflammation.

A second abdominal ultrasonography was performed that showed a fluid collection (about 70× 40 mm) in favor of appendiceal abscess in right lower quadrant (Figure 2). The patient was scheduled for spiral abdomen-pelvic computed tomographic scan which showed a hypodense well defined collection with air fluid level (about 70× 40× 30 mm) in right lower quadrant. The collection was extended to pelvic cavity associated with inflammation of the surrounding fat in favor of appendiceal abscess (Figure 3).

The consulted surgeon recommended antibiotic therapy and close follow up. One week after antibiotic therapy a third abdominal ultrasonography was performed that showed a smaller fluid collec-

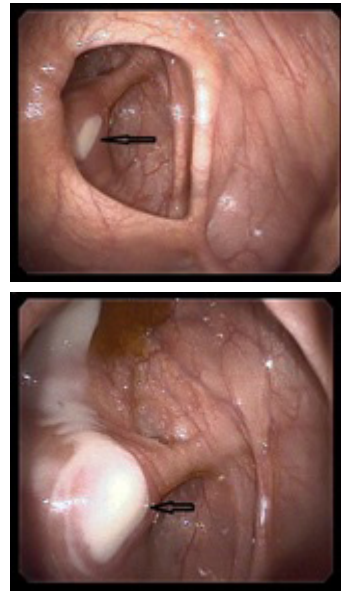


Fig. 1: Purulent discharge from the appendiceal orifice before (up) and after (down) pressing by forceps (arrow)

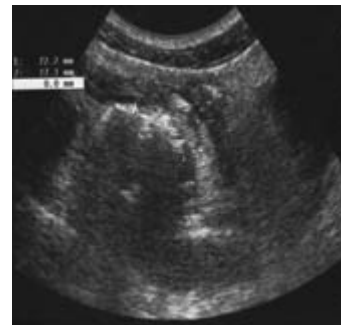


Fig. 2: Ultrasonography showing a fluid collection in favor of appendiceal abscess

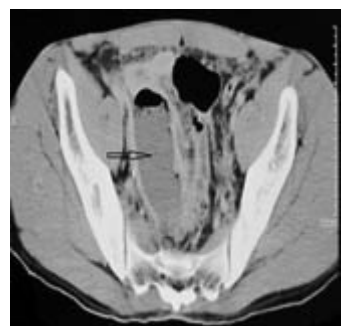


Fig. 3: Computed tomographic scan showing a hypodense well defined collection with air fluid level associated with inflammation of surrounding fat in favor of appendiceal abscess (arrow).

tion (about 40× 15 mm) around the appendix. Three weeks after antibiotic therapy the patient was asymptomatic with normal white blood cell count. On the 5th week after antibiotic therapy, exploratory laparotomy did not show any mass or collection in the appendiceal region and elective appendectomy was performed. The postoperative course of patient was uneventful. After 3 months of follow-up the patient was well without any complaint or physical finding.

DISCUSSION

Acute appendicitis is one of the most frequent causes of acute abdomen. Despite the use of scores in the radiological evaluation, and laparoscopic advances, some cases of appendicitis are reported to be complicated, due to delayed diagnosis. Ideal therapeutic approach for acute complicated appendicitis is controversy. Aranda-Narváez JM et al. in a cohort study of patients with appendiceal abscess or phlegmon due to acute appendicitis concluded that initial conservative treatment should be considered.¹

Colonoscopy is reported as a diagnostic and therapeutic approach for delayed or atypical presentations of acute appendicitis.²⁻⁹ Our patient is one of these unusual cases among whom complicated acute appendicitis was incidentally diagnosed by colonoscopy.

Although the appendiceal orifice is routinely examined during colonoscopy, however there are only few published reports describing acute appendicitis diagnosis in the appendiceal orifice.

In a review article, Khawaja FI recommended that colonoscopy should only be done in selected patients with atypical appendicitis or uncertain diagnosis of appendiceal perforation.¹⁰

Benatta MA reported an atypical case of pericecal appendiceal abscess diagnosed and treated at colonoscopy, while initial presentation was without any suggestive symptoms of appendicitis.⁴

Wade AD et al reported an atypical case of appendicitis in a patient with ulcerative colitis diagnosed during colonoscopy. In this report the initial CT scan and abdominal ultrasonography were normal.²

Christoffersen MMW et al reported an atypical case of periappendicular abscess diagnosed and treated at colonoscopy, while the patient was admitted for colonoscopy polyp control without any suggestive symptoms.⁸

Kawahara Y et al reported a case of appendiceal abscess with draining pus from appendiceal into the lumen diagnosed at colonoscopy and CT scan. In this report because of spontaneous drainage of abscess into the lumen, the appendiceal abscess had resolved by the time of surgery.⁵

Kapral C et al. reported a case of pericecal abscess that treated by drainage at colonoscopy and antibiotic therapy. They intubated the appendix by sphincterotomomy catheter which was placed into the abscess cavity.⁶

Petro M reported a case of the earliest stage of acute appendicitis in an asymptomatic patient undergoing colonoscopy for evaluation of colorectal cancer.⁹

For evaluation of the role of colonoscopy in the diagnosis of atypical appendicitis, a retrospective study in 21 patients performed by Chang HS et al. They concluded that colonoscopy may be useful in these cases.³

Some of acute appendicitis cases are reported to be complicated, due to delayed diagnosis. This unusual case highlights a patient with an appendiceal abscess diagnosed by colonoscopy. Because of spontaneous drainage of abscess into the lumen of colon and antibiotic therapy, the appendiceal abscess had resolved by the time of surgery. Although the diagnostic and therapeutic role of colonoscopy in these patients is uncertain, however, it's use can be selected in special situations in the future.

CONFLICT OF INTEREST

The authors declare no conflict of interest related to this work.

REFERENCES

1. Aranda-Narváez JM, González-Sánchez AJ, Marín-Camero N, Montiel-Casado C, López-Ruiz P, Sánchez-Pérez B, et al. Conservative approach versus urgent appendectomy in surgical management of acute appendicitis with abscess or phlegmon. *Rev Esp Enferm Dig* 2010;**102**:648-52.

2. Wade AD, Aberger FJ. Colonoscopic Diagnosis of Appendicitis in a Patient with Ulcerative Colitis: A Case Report and Review of the Literature. *Gunder Luth Med J* 2009;**6**:14-7.
3. Chang HS, Yang SK, Myung SJ, Jung HY, Hong WS, Kim JH, et al. The role of colonoscopy in the diagnosis of appendicitis in patients with atypical presentations. *Gastrointest Endosc* 2002;**56**:343-8.
4. Benatta MA. Incidental Diagnostic and Treatment of a Suppurative Appendicitis at Colonoscopy. *Case Rep Med* 2012;**2012**:523708.
5. Kawahara Y, Kawahara H, Ishikawa H, Yanaga K. Spontaneous drainage of Appendiceal abscess into the cecum. *Jikeikai Med J* 2011;**58**:121-4.
6. Kapral C, Wewalka F, Ziachehabi A, Schoefl R. Pericecal abscess treated by endoscopic transappendiceal stenting. *Endoscopy* 2012;**44**:E310.
7. Said M, Ledochowski M, Dietze O, Simader H. Colonoscopic diagnosis and treatment of acute appendicitis. *Eur J Gastroenterol Hepatol* 1995;**7**:569-71.
8. Christoffersen MW, Bulut O, Jess P. Colonoscopic Diagnosis and Treatment of Periappendicular Abscess. *World J Colorect Surg* 2008;**1**:1-13.
9. Petro M, Minocha A. Asymptomatic early acute appendicitis initiated and diagnosed during colonoscopy: A case report. *World J Gastroenterol* 2005;**11**:5398-400.
10. Khawaja FI. Diseases of the appendix recognized during colonoscopy. *Saudi J Gastroenterol* 2002;**8**:43-52.