

Pediatric Hydrostatic Intussusception Reduction - Still a Clinician's Enigma: A Case Report

Vikrant Sood^{1*}, Rajeev Khanna¹, Deepak Jain²

1. Department of Pediatric Hepatology, Institute of Liver and Biliary Sciences, New Delhi, India
2. Department of Radiology, Institute of Liver and Biliary Sciences, New Delhi, India

ABSTRACT

We present a case of infantile intussusception treated successfully using hydrostatic reduction, highlighting the importance of non-surgical techniques as the first line of management for this entity. Physicians should strive for mastery over such techniques by extensive training to prevent unwanted surgical procedures in such cases.

KEYWORDS

Intussusception; Hydrostatic reduction; Non-surgical techniques.

Please cite this paper as:

Sood V, Khanna R, Jain D. Pediatric Hydrostatic Intussusception Reduction - Still a Clinician's Enigma: A Case Report. *Middle East J Dig Dis* 2012;4:177-9.

INTRODUCTION

Acute intussusception is one of the most common causes of acute abdomen in infants.¹ Management includes both surgical and non-surgical methods, with gradually increasing importance recently being accorded to the latter. Conservative measures, including hydrostatic reduction, are the methods of choice for initial management. Though widely accepted, the expertise is still not widely available, especially in developing countries. We hereby report a case of infantile intussusception managed successfully with hydrostatic reduction.

CASE REPORT

A six-month-old child presented with complaints of repeated episodes of vomiting that contained only ingested milk. This was associated with three episodes of loose stools, initially watery and later with fresh red blood per rectum with jelly-like consistency. There was no history of fever, decreased urine output, lethargy, abnormal body movements, or difficulty in breathing. The child was started on top-feeds for the past one month. Her immunizations were fully up to date with no history of Rota virus immunization.

On admission her general condition was stable with some dehydration. Abdominal examination was remarkable for an ill-defined mass that could be felt in the right hypochondrium. Her initial working diagnosis was rectal bleeding with possibility of intussusception.

She was initially kept nil per oral and started on conservative measures, including antibiotics. An urgent abdominal ultrasonography was

* Corresponding Author:

Vikrant Sood, MD
Department of Pediatric Hepatology,
Institute of Liver and Biliary Sciences,
New Delhi, India.
Tel: +91 97 11143397
Email: drvickyster@gmail.com
Received: 21 Jan. 2012
Accepted: 22 Mar. 2012

done, which showed a round mass-like lesion giving a target appearance in the right hypochondrium (Suggestive of Ileocolic intussusception). She was taken for immediate intervention, and as per surgical opinion, a hydrostatic reduction under radiological guidance was started.

The child was first stabilized using intravenous fluids to treat dehydration, and a pre-procedure x-ray abdomen was performed to rule out intestinal perforation. The procedure was done in the ultrasonography room in the presence of a treating physician and a pediatric surgeon. Without using any sedation, a 16 F Foley catheter was inserted into the rectum in the supine position and the balloon was gently inflated while maintaining a tight anal seal.

The patient's vitals, which included abdominal girth and distension, were monitored throughout the procedure. Ringer's lactate solution, warmed to body temperature, was then slowly introduced into the catheter through a bag hanging at a height of approximately 100 cm. During reduction, the intussusceptum was observed under continuous ultrasound guidance as it proceeded to the cecum and then reduced across the ileocecal valve (Figures 1-4).

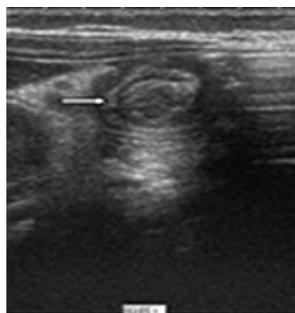


Fig 1: Loop within loop, ileocolic intussusception (arrow), axial view.

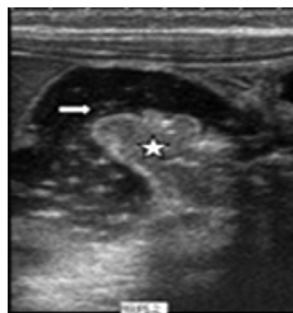


Fig 2: Ileal loop (star) within ascending colon (arrow), longitudinal view.

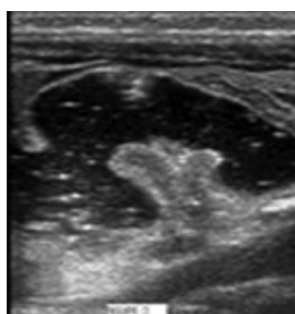


Fig 3: During reduction

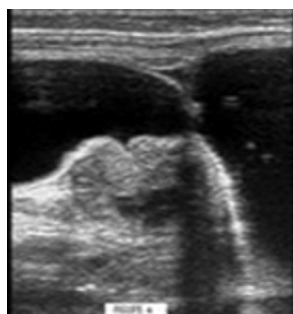


Fig 4: Complete reduction

This was associated with the patient's improved condition, which included less crying and irritability. Thereafter, the child was restarted on food with no recurrence of her symptoms. A repeat ultrasound was normal. The parents were told about the possibility of recurrence and asked to pay close attention for the onset of symptoms.

DISCUSSION

Acute intussusception is defined as the telescoping of the proximal bowel (intussusceptum) into the distal bowel (intussusciens). The usual locations include the ileocolic region and ileocecal junction, which comprise the majority of cases. Intussusception mostly presents between four months and two years, while the peak incidence is found around middle infancy.²

Diagnosis usually needs a high suspicion on the part of the treating physician, as presentation can be quite varied, including irritability, vomiting, and poor feeding. Characteristic manifestations include crying episodes, fresh red blood in stools (hematochezia), and a mass in the abdomen. Differential diagnoses include acute gastroenteritis, dysentery, sepsis syndrome, and volvulus, amongst others. Thus a close watch over the entire clinical picture is recommended.

The diagnosis is usually confirmed sonographically, which is highly accurate and has a reported sensitivity that exceeds 90%. Various signs have been described in the literature, depicting intussusception as an abdominal mass with a target sign on the transverse section, a pseudokidney (or sandwich sign) on the longitudinal section,³ and a crescent-in-doughnut sign on axial images.⁴

The management of intussusception has seen a paradigm shift in recent years. In the past, the preferred non-surgical method involved use of a barium enema for reduction, followed by the air insufflation method.⁵

Initially described by Kim et al. in 1982, hydrostatic reduction using ultrasound-guided saline reduction has recently gained acceptance as the procedure of choice for initial nonsurgical management of intussusceptions in children. This popularity can be attributed to the avoidance of radiation exposure to the child and the treating team, as well as to the high success rates that have been achieved.⁶

There is still some controversy regarding the exact

method of the procedure, which can be attributed to the poor training of physicians and to the general belief that intussusception is entirely a surgical problem, especially in developing countries. This procedure should be undertaken with a close liaison between pediatrics, pediatric surgery, and radiology teams to obtain the best results. The surgeon and physician should always be present at the time of reduction for clinical monitoring.

After adequate optimization, including temperature controlled settings, the procedure should ideally be undertaken without any sedation. This is helpful for assessing a successful reduction using clinical criteria, as described later.

We used Ringer's lactate due to its near physiological constitution, avoiding the risk of chemical peritonitis due to a barium enema or tension pneumoperitoneum due to an air enema, as seen in cases of intestinal perforation.⁷ The risk of intestinal perforation following such a procedure is rarely encountered due to less hydrostatic pressure exerted and an even amount of pressure exerted on the bowel walls as compared to air insufflations.⁸ Even if intestinal perforation occurs, it can immediately be recognized using sonography.⁵

We chose 100 cm H₂O pressure to lessen the risk of perforation, though different studies have used a wide range of pressures (75 to 125 cm H₂O).^{6,9}

The main ultrasonographical criteria of successful reduction is the flow of the fluid from the cecum into the terminal ileum. General improvement in the clinical profile of the patient including relief from crying, stable vitals, increasing abdominal distension during the procedure (which indicates filling of the small bowel), and the disappearance of the abdominal mass, should also be given due consideration when deciding to terminate the procedure.⁶

A repeat ultrasound should always be done after the procedure as the chances of recurrence is high, especially in the immediate post-procedure period. This should be carefully communicated to the parents.

In brief, this method should be undertaken as teamwork, and not considered the work of a single specialty, which is the best way of treating the patients according to the standards of today.⁶

CONFLICT OF INTEREST

The authors declare no conflict of interest related to this work.

REFERENCES

1. Munden MM, Bruzzi JF, Coley BD, Munden RF Sonography of pediatric small-bowel intussusception: differentiating surgical from nonsurgical cases. *Am J Roentgenol* 2007;**188**:275-9.
2. Huppertz HI, Soriano-Gabarró M, Grimpel E, Franco E, Mezner Z, Desselberger U, et al. Intussusception among young children in Europe. *Pediatr Infect Dis J* 2006;**25**: S22-9.
3. Harrington L, Connolly B, Hu X, Wesson DE, Babyn P, Schuh S. Ultrasonographic and clinical predictors of intussusception. *J Pediatr* 1998;**132**:836-9.
4. Del-Pozo G, Albillos JC, Tejedor D. Intussusception: US findings with pathological correlation- the crescent-in-doughnut sign. *Radiology* 1996;**199**:688-92.
5. Daneman A, Navarro O. Intussusception. Part 2: An update on the evolution of management. *Pediatr Radiol* 2004;**34**:97-108.
6. Tander B, Baskin D, Candan M, Başak M, Bankoğlu M. Ultrasound guided reduction of intussusception with saline and comparison with operative treatment. *Ulus Travma Acil Cerrahi Derg* 2007;**13**:288-93.
7. Chan KL, Saing H, Peh WC, Mya GH, Cheng W, Khong PL, et al. Childhood intussusception: Ultrasound-guided Hartmann's solution hydrostatic reduction or barium enema reduction? *J Pediatr Surg* 1997;**32**:3-6.
8. Zambuto D, Bramson RT, Blickman JG. Intracolonic pressure measurements during hydrostatic and air contrast barium enema studies in children. *Radiology* 1995;**196**:55-8.
9. González-Spínola J, Del Pozo G, Tejedor D, Blanco A. Intussusception: the accuracy of ultrasound-guided saline enema and the usefulness of a delayed attempt at reduction. *J Pediatr Surg* 1999;**34**:1016-20.