

Surgical Management of Localized Crohn's Disease of the Fourth Part of the Duodenum

M Mozafar^{1*}, MR Sobhiyeh¹, N Tadayon¹, N Khalegnejad Tabari¹, N Bolouri¹

1. Department of General and Vascular Surgery, Shohada-Tajrish Medical Center, Shahid Beheshti University of Medical Sciences, Tehran, Iran

ABSTRACT

Upper gastrointestinal tract (gastroduodenal) Crohn's disease (CD) is an uncommon condition, occurring in about 1-5% of all CD cases. Our case was an extremely rare manifestation of CD, who presented with distal duodenal obstruction. As preoperative diagnosis was not established he underwent segmental resection and end-to-end anastomosis. Postoperative small bowel fistulae were not observed, and there was no morbidity during the follow up period. There were no disturbances in digestive function.

KEYWORDS

Crohn's disease; Surgical management; Duodenum

INTRODUCTION

Crohn's disease (CD) involves the small intestine only in 19.3%, large intestine in 35.7%, and both the small and large intestine in 44% of patients.¹

Upper gastrointestinal tract (gastroduodenal) CD is an uncommon condition, occurring in about 1-5% of all CD cases.^{1,2}

It usually involves the first and second parts of the duodenum and presents with peptic ulcer-like abdominal pain and symptoms of gastric outlet obstruction.

Involvement of the fourth part of the duodenum is very rare and found in only about 10% of cases with CD of the duodenum.³ We describe the surgical management of a patient with distal duodenal CD, who presented with symptoms of proximal intestinal obstruction.

CASE REPORT

A 49 year-old man was referred for postprandial vomiting. He had complaints of occasional vomiting for two years, but his symptoms worsened two months prior to his referral, when he experienced vomiting with increasing frequency accompanied by epigastric pain and fullness.

An upper gastrointestinal endoscopy was performed, which was unremarkable, except for a dilated stomach and dilated first and second parts of the duodenum.

Laboratory tests, including a complete blood cell count, liver and renal function tests, and electrolytes were all normal.

The patient's inflammatory markers (erythrocyte sedimentation rate and C-reactive protein) were normal.

*Corresponding Author:

Mohamad Mozafar, MD,
Associate Professor, Department of
General and Vascular Surgery,
Shohada-Tajrish Medical Center,
Shahid Beheshti University of Medical
Sciences, Tehran, Iran
Telefax: +98 21 22721144
E-mail: mohamad_mozafar@yahoo.com
Received: 2 September 2009
Accepted: 16 November 2009

Further imaging studies were followed by a small bowel barium follow-through (Figure 1), which showed a dilated stomach and duodenum, and a stricture in the distal duodenum. Abdominal CT-scan (Figure 2) showed that the stricture was caused by an infiltrative mass.

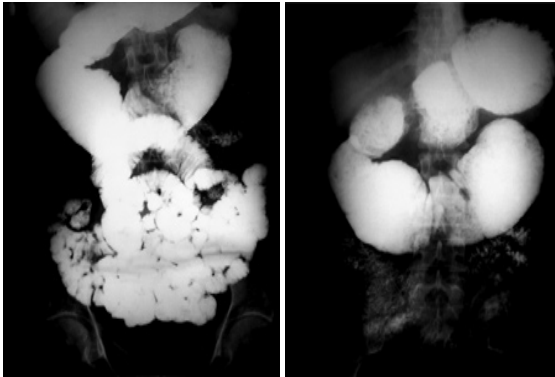


Figure 1: Small bowel barium follow through, showing a dilated stomach and duodenum, and a stricture in the distal duodenum.

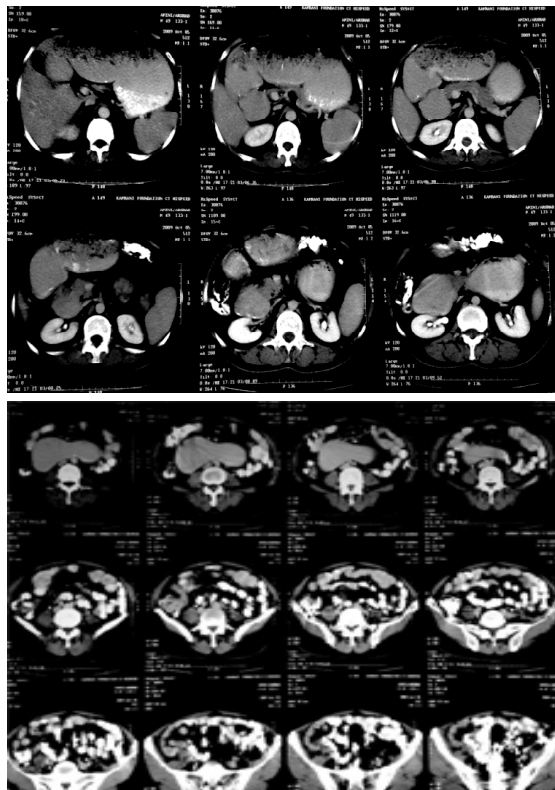


Figure 2: CT-scan showing the stricture caused by an infiltrative mass.

Surgical resection of the tumor was planned. An upper midline laparotomy was performed and an infiltrative intestinal tumor (7.5 cm in length and 3.5 cm greatest diameter) was seen at the ligament of Treitz with thickening of the mesentery and surrounding fat wrapping. Mesenteric induration and enlarged lymph nodes were present (Figure 3).

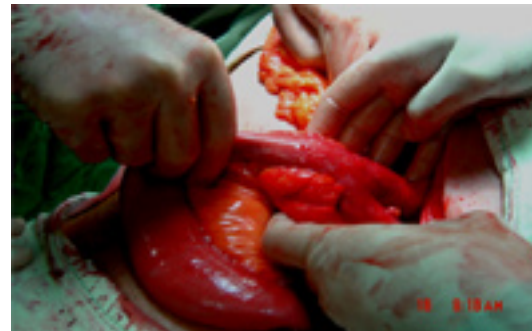

Figure 3: An infiltrative intestinal tumor (7.5 cm in length and 3.5 cm greatest diameter) was seen at the ligament of Treitz with thickening of the mesentery and surrounding fat wrapping.

The mass was resected and sent for frozen section, and was reported to be an inflammatory benign lesion. A primary duodenojejunal anastomosis was performed. The patient had an event-free hospital course. Histopathological examination of the mass revealed distorted glandular architecture and mucosal ulceration with dense transmural infiltration of inflammatory cells, including lymphocytes, plasma cells, eosinophils and lymphoid follicle formations with predominance of inflammation in the mucosa and submucosa, compatible with CD. His postoperative course was uneventful and he has remained asymptomatic during the follow-up period.

DISCUSSION

CD is a chronic pan-enteric inflammatory disease of unknown etiology. Although CD can affect the entire gastrointestinal tract, gastroduodenal involvement is rarely seen and occurs in approximately 1-2% of CD patients. According to the literature, about 165 cases have been reported in small series.^{1,4,5}

Duodenal CD presents with with epigastric pain, weight loss, anemia, low grade fever, sometimes intermittent diarrhea and arthritis/arthralgia.

Upper abdominal pain and symptoms of gastroduodenal obstruction are the most common patterns of presentation. Duodenal CD occasionally develops first in the duodenum but rarely does the disease remain confined there.

The most common pattern of involvement is contiguous disease of the proximal duodenum and distal stomach. Endoscopically, diffuse granularity, nodularity and ulceration are seen accompanied by lack of distensibility of the involved area.

Granulomas are rarely found in endoscopic biopsies.⁵ Compared to patients with an ileocolonic localization, patients with CD in the upper gastrointestinal tract more frequently have colic-like abdominal pain and/or cramps and are younger at disease onset.⁴ Barium x-ray studies show aphthous ulcers in the stomach and duodenum with distal ileum lesions and deformity.

A diagnosis of CD of the upper gastrointestinal tract can be achieved by combining recognition of clinical, roentgenographic and endoscopic features. Medical therapeutic principles are the same as for CD elsewhere in the gastrointestinal tract.

Corticosteroids and proton pump inhibitors are used for disease control. Absolute indications for surgical treatment are massive bleeding, progressive stenosis and extensive fistula formation.⁴ When the patient develops obstruction surgery usually becomes mandatory.⁴

CD has the tendency to reoccur. Until now, it has been impossible to heal this disease either by medical or surgical management.⁶

The principle of timely and minimally invasive surgical procedure has been generally adopted and although treatment of CD of the small intestine is at present principally medical, in the majority of cases surgical intervention is unavoidable. Experience has shown that surgery should be as conservative as possible.⁷

For obstructing duodenal CD, bypass procedures or segmental resection and end-to-end anas-

tomosis have traditionally been selected.⁸ However duodenal resection for inflammatory disease is hazardous⁹ and unlike the management of CD in other parts of the gastrointestinal tract, bypass is favored over resection for duodenal CD.¹⁰

Although suggested, gastrojejunostomy bypass for the treatment of obstructing duodenal CD¹¹ is accompanied by increased incidence of stomal ulcers.

Routine addition of vagotomy has been proposed to overcome this complication,⁸ but vagotomy may even worsen the diarrhea in CD.¹² Others demonstrate no role for vagotomy in bypass procedures.¹⁰

On the other hand, a bypassed or excluded segment of small bowel involved with CD is associated with an increased risk of adenocarcinoma.¹¹

More recently strictureplasty has become an acceptable surgical option.

Our case was an extremely rare case of CD with the presentation of distal duodenal obstruction. As preoperative diagnosis was not established he underwent segmental resection and end-to-end anastomosis. Postoperative small bowel fistulae were not observed and there was no morbidity during the follow up period. There were no disturbances in digestive function.

CONFLICT OF INTEREST

None declared.

REFERENCES

1. Vahedi H, Merat S, Momtahn S, Olfati G, Kazzazi AS, Tabrizian T, et al. Epidemiologic characteristics of 500 patients with inflammatory bowel disease in Iran studied from 2004 through 2007. *Arch Iran Med* 2009;**12**:454-60.
2. Orda R, Sayfan J, Carmeli Y, Scapa E. Surgical treatment for Crohn's disease of the fourth part of the duodenum. *J R Soc Med* 1990;**83**:802-3.
3. Malleson P. Isolated gastroduodenal Crohn's disease in a ten-year-old girl. *Postgrad Med J* 1980;**56**:294-6.
4. Wagtmans MJ, van Hogezaand RA, Griffioen G, Verspaget HW, Lamers CB. Crohn's disease of the upper gastrointestinal tract. *Neth J Med* 1997;**50**:S2-7.
5. Abrahão LJ Jr, Abrahão LJ, Vargas C, Chagas V, Fogaça H. Gastroduodenal Crohn's disease - report of 4 cases and review of the literature. *Arq Gastroenterol* 2001;**38**:57-62.

6. Popović M, Petrović M, Matic S, Milovanović A. The role of strictureplasty in the treatment of Crohn's disease. *Acta Chir Lugosl* 2002;**49**:9-14.
7. Lee EC, Papaioannou N. Minimal surgery for chronic obstruction in patients with extensive or universal Crohn's disease. *Ann R Coll Surg Engl* 1982;**64**:229-33.
8. Greenstein AJ. The surgery of Crohn's disease. *Surg Clin North Am* 1987;**67**:573-96.
9. Murray JJ, Schoetz DJ Jr, Nugent FW, Collier JA, Veidenheimer MC. Surgical management of Crohn's disease involving the duodenum. *Am J Surg* 1984;**147**:58-65.
10. Shapiro M, Greenstein AJ, Bym J, Corona J, Greenstein AJ, Salky B, et al. Surgical management and outcomes of patients with duodenal Crohn's disease. *J Am Coll Surg* 2008;**207**:36-42.
11. Ross TM, Fazio VW, Farmer RG. Long-term results of surgical treatment for Crohn's disease of the duodenum. *Ann Surg* 1983;**197**:399-406.
12. Kyle J. Gastroduodenal involvement in Crohn's disease. *J R Coll Surg Edinb* 1982;**27**:327-32.