



Case Report

L-Shaped Configuration of Multiple Magnet Ingestion: A Case Report

Mehran Hakimzadeh¹, Mitra Ahmadi¹, Hazhir Javaherizadeh¹

¹Alimentary Tract Research Center, Clinical Sciences Research Institute, Imam Khomeini Hospital, Ahvaz Jundishapur University of Medical Sciences, Ahvaz, Iran

Abstract

Multiple magnet ingestion is an urgent situation in pediatric gastroenterology that requires endoscopy or surgical intervention to remove the magnet. We report a case in which multiple magnets attract each other in a special geometric shape in the gastrointestinal tract of a 2-year-old boy.

Keywords: Gastric, Magnets, Stomach

Cite this article as: Hakimzadeh M, Ahmadi M, Javaherizadeh H. L-shaped configuration of multiple magnet ingestion: a case report. *Middle East J Dig Dis* 2025;17(1):76-78. doi: 10.34172/mejdd.2025.410.

Received: August 5, 2024, **Accepted:** November 28, 2024, **ePublished:** January 31, 2025

Introduction

Foreign body ingestion is a potentially serious problem that peaks between 6 months to 3 years.¹ Most of the foreign bodies were asymptomatic and require follow-up. However, some foreign bodies that cause intestinal obstruction require endoscopic or surgical procedures.² Because multiple magnet ingestion may be asymptomatic, physicians must be aware of the possibility of multiple magnet ingestion because serious complications such as bowel perforation may occur.³

There are several reports of multiple magnet ingestion in the literature. However, reports of the interesting shapes of multiple magnet ingestion are limited.⁴ Multiple magnets attract each other, but some geometric alignments may be of interest. Also, gastric perforation is a very important complication of multiple magnets ingestion and should be considered in children. Here in, L-shaped multiple magnet ingestion was reported.

Case Report

A 2-year-old Asian boy with multiple magnet ingestion was referred to our hospital. Magnet ingestion occurred during 24-48 hours before admission. Physical examination revealed no problem. Following abdominal radiography, multiple foreign bodies were seen in an interesting alignment (Figures 1 and 2). Evidence of gastric perforation was not seen in the radiographs, so an upper gastrointestinal endoscopy was done. Multiple magnets that penetrated gastric mucosa were seen (Figure 3). One magnet was removed using endoscopy with a snare and basket. Some magnets were inserted in the gastric tissue, so the patient was referred to a pediatric surgeon for removing other magnets.

Discussion

Single magnet ingestion causes no problem, but multiple magnet ingestion may cause some problems for children. They should be removed as soon as possible using an endoscopic procedure or surgery.

In a recently published systematic review, 63.6% of children who ingested magnetic foreign bodies were male.⁵ Complications following multiple magnet ingestions were described in the literature.⁶ Bowel obstruction, bowel perforation,^{7,8} entero-enteric fistula,⁹ intestinal volvulus¹⁰ were reported. Intestinal volvulus and perforation were done following multiple magnet ingestion, as reported by Ilce and colleagues.¹¹ Arslan and colleagues reported jejunoileal perforation following multiple magnet ingestion in a 3-year-old child.¹² Also, De Raeymaeker et al reported a 2-year-old child with multiple magnet ingestion and intestinal perforation.⁶

In this case, due to gastric perforation, surgical intervention was done. Surgical treatments of multiple magnet ingestion were reported in the literature.¹³

For a diagnostic approach for children with suspected magnet ingestion, magnetic resonance imaging (MRI) is contraindicated. Perforation following MRI in children with unwitnessed magnet ingestion was reported.¹⁴ Recently, a high-frequency ultrasound was recommended to diagnose magnet ingestion.¹⁵

In children without a history of magnet ingestion, magnet ingestion should be one of diagnoses.¹⁶ Peyron and co-workers reported a 6-year-old child who died after the onset of nausea and abdominal pain without a history of magnet ingestion. The autopsy showed diffused peritonitis and perforation of the transverse colon with multiple high-power magnets.¹⁶



*Corresponding Author: Hazhir Javaherizadeh, Email: hazhirja@yahoo.com



© 2025 The Author(s). This work is published by Middle East Journal of Digestive Diseases as an open access article distributed under the terms of the Creative Commons Attribution License (<http://creativecommons.org/licenses/by/4.0/>), which permits unrestricted use, distribution, and reproduction in any medium, provided the original work is properly cited.

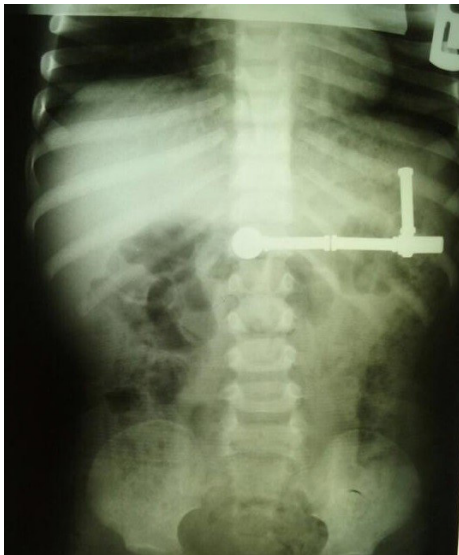

Figure 1. Multiple magnets in interesting alignment

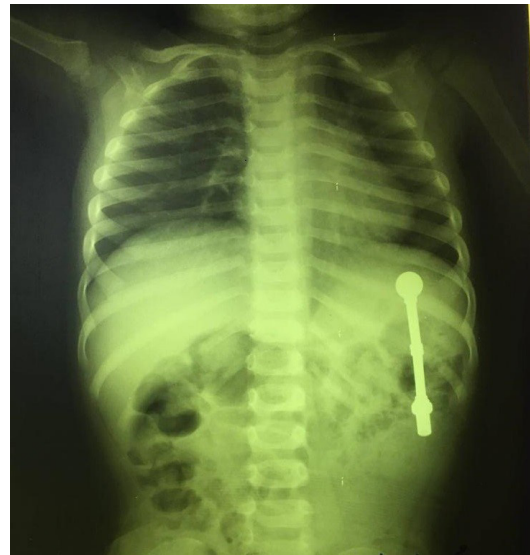

Figure 2. Magnets in the left upper quadrant

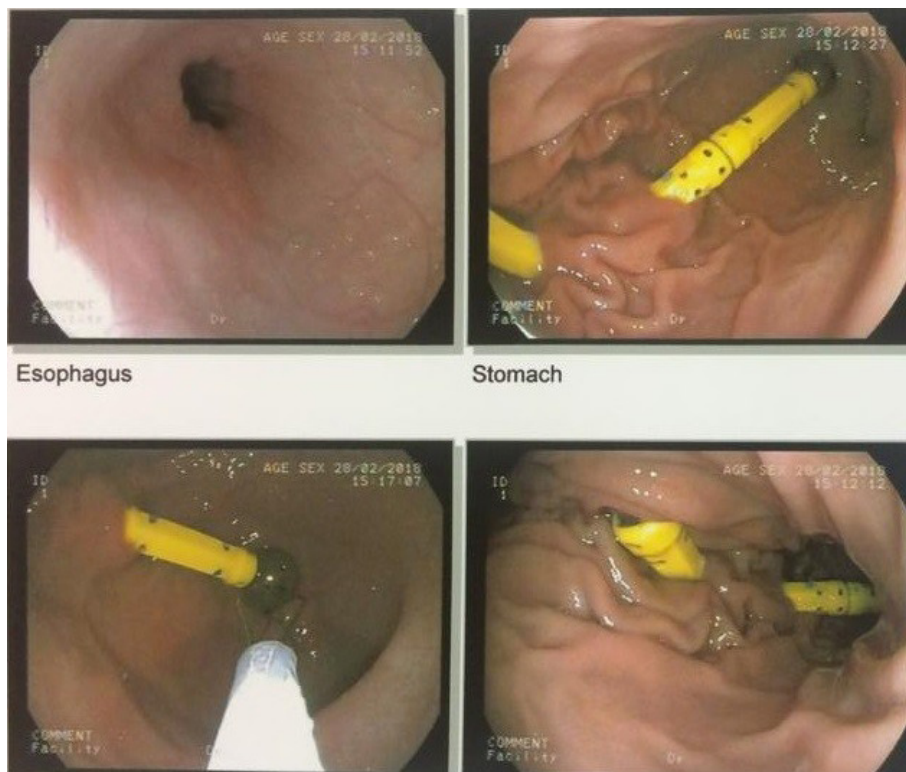


Figure 3. Multiple magnets penetrating gastric mucosa

Conclusion

Multiple magnet ingestion should be suspected in any child with a history of foreign body ingestion. Even without a history of foreign body ingestion, multiple magnet ingestion is one of the differential diagnoses in children who visit the hospital or clinics with gastrointestinal problems.¹⁶ Careful investigation is mandatory. Endoscopic and surgical intervention may be required.

Authors' Contribution

Investigation: Mehran Hakimzadeh.

Supervision: Mehran Hakimzadeh.

Writing—original draft: Mitra Ahmadi, Hazhir Javaherizadeh.

Writing—review & editing: Mitra Ahmadi, Hazhir Javaherizadeh.

Competing Interests

The authors have no conflicts of interest to declare related to this work.

Consent for Publication

Written informed consent was signed by the parents.

Funding

None.

References

- Arana A, Hauser B, Hachimi-Ildrissi S, Vandenplas Y. Management of ingested foreign bodies in childhood and review of the literature. *Eur J Pediatr* 2001;160(8):468-72. doi: [10.1007/s004310100788](https://doi.org/10.1007/s004310100788)
- Ghoroubi J, Imanzadeh F, Sayyari AA, Javaherizadeh H. Foreign body impacted in the jejunum. *Ann Pediatr Surg* 2010;6(1):36-40.
- Tavarez MM, Saladino RA, Gaines BA, Manole MD. Prevalence, clinical features and management of pediatric magnetic foreign body ingestions. *J Emerg Med* 2013;44(1):261-8. doi: [10.1016/j.jemermed.2012.03.025](https://doi.org/10.1016/j.jemermed.2012.03.025)
- Mili T, Charieg A, Ahmed YB, Marzouki M, Nouira F, Jlidi S. A case report of multiple foreign body ingestion with a ring-like configuration: the magnetic effect. *Int J Surg Case Rep* 2023;106:108177. doi: [10.1016/j.ijscr.2023.108177](https://doi.org/10.1016/j.ijscr.2023.108177)
- Xie S, Bai J, Huang Y, Lin S, Zhang H, Fang Y, et al. Clinical characteristics and interventions for ingested magnetic foreign bodies in children: a systematic review and meta-analysis. *Indian Pediatr* 2023;60(5):397-403.
- De Raeymaeker X, Van Cauwenbergh S, Houben B, Karimi A, Sergeant G, Appeltans B. Magnets and children: a dangerous combination. *Acta Chir Belg* 2024;124(2):156-9. doi: [10.1080/00015458.2023.2219086](https://doi.org/10.1080/00015458.2023.2219086)
- Lee BK, Ryu HH, Moon JM, Jeung KW. Bowel perforations induced by multiple magnet ingestion. *Emerg Med Australas* 2010;22(2):189-91. doi: [10.1111/j.1742-6723.2010.01276.x](https://doi.org/10.1111/j.1742-6723.2010.01276.x)
- Wong HH, Phillips BA. Opposites attract: a case of magnet ingestion. *CJEM* 2009;11(5):493-5. doi: [10.1017/s1481803500011696](https://doi.org/10.1017/s1481803500011696)
- Nguyen BP, Ahuja N, Barthel ER. Chronic small bowel fistulas, entero-mesenteric fistulas, and entrapped bezoar after ingestion of 2.5-mm magnetic beads. *J Pediatr Surg Case Rep* 2023;89:102542. doi: [10.1016/j.epsc.2022.102542](https://doi.org/10.1016/j.epsc.2022.102542)
- Nui A, Hiramata T, Katsuramaki T, Maeda T, Meguro M, Nagayama M, et al. An intestinal volvulus caused by multiple magnet ingestion: an unexpected risk in children. *J Pediatr Surg* 2005;40(9):e9-11. doi: [10.1016/j.jpedsurg.2005.05.065](https://doi.org/10.1016/j.jpedsurg.2005.05.065)
- Ilçe Z, Samsun H, Mammadov E, Celayir S. Intestinal volvulus and perforation caused by multiple magnet ingestion: report of a case. *Surg Today* 2007;37(1):50-2. doi: [10.1007/s00595-006-3330-6](https://doi.org/10.1007/s00595-006-3330-6)
- Arslan S, Basuguy E, Zeytun H, Okur MH, Aydogdu B, Arslan MS. Jejunoileal perforation and volvulus caused by multiple magnet ingestion. *Acta Clin Croat* 2015;54(1):96-8.
- Zhang C, Zhang XW, Liu SM, Huang KH, Chen ZM. Surgical treatment of multiple magnet ingestion by children: a single-center experience from China. *Qatar Med J* 2024;2024(1):4. doi: [10.5339/qmj.2024.4](https://doi.org/10.5339/qmj.2024.4)
- Bailey JR, Eisner EA, Edmonds EW. Unwitnessed magnet ingestion in a 5-year-old boy leading to bowel perforation after magnetic resonance imaging: case report of a rare but potentially detrimental complication. *Patient Saf Surg* 2012;6(1):16. doi: [10.1186/1754-9493-6-16](https://doi.org/10.1186/1754-9493-6-16)
- Xin Y, Jia LQ, Dong YW, Wang Y, Hu YX, Wang XM. Application of high-frequency ultrasound in the diagnosis of gastrointestinal magnet ingestion in children. *Front Pediatr* 2022;10:988596. doi: [10.3389/fped.2022.988596](https://doi.org/10.3389/fped.2022.988596)
- Peyron PA, Villard C, Baccino E. Fatal bowel perforation caused by ingestion of high-powered magnets in a 6-year-old boy. *Int J Legal Med* 2024;138(4):1659-62. doi: [10.1007/s00414-024-03188-1](https://doi.org/10.1007/s00414-024-03188-1)