



## Case Report

# Caroli's Disease Associated with Autosomal Dominant Polycystic Kidney Disease with Acute Pancreatitis: A Case Report

Karishma M Rathi<sup>1</sup>, Priyanka Pingat<sup>1</sup>, Prachi Bansode<sup>1</sup>, Shaili Dongare<sup>1</sup>

<sup>1</sup>Department of Pharmacy Practice at Dr. D.Y. Patil Institute of Pharmaceutical Sciences and Research Pimpri, Pune, India

### Abstract

A rare congenital hepatobiliary disorder called Caroli's disease is characterized by multifocal segmental dilatation of intrahepatic bile ducts that can affect the entire liver or only specific areas of it. Coexisting conditions with Caroli's disease include autosomal dominant polycystic kidney disease (ADPKD) and autosomal recessive polycystic kidney disease (ARPKD). ADPKD results in the development of cysts, which are tiny fluid-filled sacs, in the kidneys. Caroli's disease is considered a rare disorder, affecting a small number of individuals worldwide. The symptoms of Caroli's disease can vary from person to person and it also may overlap with other liver and biliary disorders. As a result, it may be challenging to diagnose and manage the condition due to limited awareness and expertise. Increased awareness, research, and specialized medical care are crucial in improving outcomes for individuals affected by this rare disorder. This study involves the case of a 60-year-old woman presented with abdominal pain, fever, weight loss, and jaundice. Her imaging test endoscopic retrograde cholangiopancreatography (ERCP) signifies Caroli's disease with pancreatic duct (PD) calculi and management involves supportive care with antibiotics. Antibiotics were prescribed to prevent or treat infections such as cholangitis and nutritional supplement was recommended in managing Caroli's disease. The patient underwent pancreatic stent placement and was discharged with regular follow-up. So, this case highlights the clinical and diagnostic aspects to improve disease understanding and the progression of Caroli's illness along with ADPKD.

**Keywords:** Autosomal dominant polycystic kidney disease, Caroli's disease, Common bile duct, Endoscopic retrograde cholangiopancreatography, Magnetic resonance cholangiopancreatography

**Cite this article as:** Rathi KM, Pingat P, Bansode P, Dongare S. Caroli's disease associated with autosomal dominant polycystic kidney disease with acute pancreatitis: a case report. *Middle East J Dig Dis* 2023;15(4):289-292. doi: 110.34172/mejdd.2023.360.

**Received:** March 9, 2023, **Accepted:** August 7, 2023, **ePublished:** October 30, 2023

### Introduction

Caroli disease is a rare genetic condition known as congenital communicating cavernous ectasia of the biliary tree, causing segmental dilation of the major intrahepatic bile duct, which, on imaging and histopathological examination, looks like cysts.<sup>1</sup> It is now understood to be a hereditary illness caused by the PKHD1 gene, which alters the fibrocystin protein and causes polycystic kidney and hepatic disease. The pancreas, liver cholangiocytes, and renal tubular cells are three organ systems where this protein is expressed. Fibrocystic alteration in the kidney and liver is brought on by genetic abnormalities in this protein.<sup>2</sup> Caroli disease only affects 1 in 100 000 people on average. A highly useful diagnostic test is magnetic resonance cholangiopancreatography.<sup>3</sup> Clinical features include jaundice, fever, and/or right hypochondrium pain.<sup>4</sup> Complications include recurrent attacks of cholangitis, abscesses, intrahepatic calculi, and growth of cholangiocarcinoma.<sup>1</sup> Caroli disease is treated with ursodeoxycholic acid for hepatolithiasis and antibiotics for cholangitis. Patients with mono- lobar disease have successfully undergone surgical resection. The preferred

medical option for patients with diffuse disease is orthotopic liver transplantation.<sup>5</sup>

### Case Report

A 60-year-old lady presented to our outpatient clinic with complaints of fever, pain in the abdomen, and loss of appetite for the last 2-3 months. She had a high-grade, continuous fever associated with chills and headaches. The abdominal pain was near the periumbilical region, which was insidious in onset, intermittent, non-progressive, non-radiating, and associated with tenderness in the umbilical region. She had lost 6 kg weight over the last 6 months. She was lean built, afebrile to touch, with a heart rate of 74 beats per minute and blood pressure of 130/80 mm Hg. She was pale and icterus positive. She had an earlier diagnosis of jaundice and comparable symptoms, including recurring fever episodes accompanied by chills, stomach discomfort, inadequate sleep, and firm stools that necessitated hospitalization 6 months prior. During her previous hospitalization, her abdominal ultrasound scan revealed Caroli's disease, suggesting focal cholangitis. The patient encountered menopause 15 years



\*Corresponding Author: Karishma M Rathi, Email: [karishma.rathi@dypvp.edu.in](mailto:karishma.rathi@dypvp.edu.in)



© 2023 The Author(s). This work is published by Middle East Journal of Digestive Diseases as an open access article distributed under the terms of the Creative Commons Attribution License (<http://creativecommons.org/licenses/by/4.0/>), which permits unrestricted use, distribution, and reproduction in any medium, provided the original work is properly cited.

ago. Her familial history was unremarkable. Meropenem 250 mg twice daily, linezolid 600 mg twice daily, metronidazole 400 mg thrice daily, paracetamol 500mg twice daily, and herbal supplements were among the previous medications in the patient's medication history. Currently, from the imaging test ERCP, it was confirmed that the patient has Caroli's disease with PD calculi. ERCP was performed to assess the extent of bile duct involvement, identify biliary stones or obstructions, and potentially treat certain complications, such as removing stones or placing stents to relieve strictures. Endoscopic ultrasound (EUS) was indicated to obtain high-resolution images, allowing for better visualization of the bile duct, identify any structural abnormalities or masses, and helping to differentiate between Caroli's disease and other conditions. Hospitalization treatment included intravenous (IV) pantoprazole 40 mg daily, ondansetron 4 mg daily, tramadol 50 mg SOS (taken as required), vitamin D3 60000 IU once a week, pheniramine maleate 2 mL SOS (taken as required), diclofenac 50 mg in 100 mL normal saline (NS) SOS (taken as required), ceftriaxone 1gm twice daily, vitamin supplements, and IV fluids. The patient received a blood transfusion due to consistently low levels of hemoglobin (Hb), packed cell volume (PCV), mean corpuscular volume (MCV) and mean corpuscular hemoglobin (MCH), which indicated anemia as shown in (Table 1). She had persistent abdominal pain and fever spikes with chills during the hospital stay, which were resolved with medications, and at the time of discharge, the patient was vitally stable without new complaints.

### Laboratory Assessment

The complete laboratory values are shown in Table 1.

### Imaging

Ultrasonography of abdomen and pelvis: Multiple anechoic cystic lesions were noted in bilateral kidneys with few specks of calcification /and septations within. EUS report: Calculi of size 7×3 mm in the head region of the pancreatic duct (PD), gall bladder was distended, and liver showed multiple anechoic cysts as shown in Figure 1. Magnetic resonance cholangiopancreatography (MRCP) demonstrated multiple small cystic formations in the liver and both kidneys, continuity of few cysts with intrahepatic biliary radicals at places, central dot sign is seen, and mild dilation of the common bile duct (CBD) with lower CBD calculus. PD stent was placed, as shown in Figure 2.

### Outcome and Follow-up

After 3 weeks of hospital stay and treatment, the patient's symptoms, such as fever with chills and abdominal pain, resolved, which showed she was able to ambulate home and to carry out her daily activities. The patient was prescribed oral pantoprazole 40 mg daily, tramadol 500 mg twice daily, cefixime 200 mg twice daily, and ondansetron 4 mg SOS to continue for 7 days, and was

**Table 1.** Laboratory values

Variables	Date			
	19/1/2023	30/1/2023	1/2/2023	6/2/2023
HB (g/dL)	9.30↓	9.90↓	9.50↓	8.70↓
WBC (/μL)	6300	5800	10700↑	10600↑
ESR (mm/h)	54↑	10 ↓	59↑	
Neutrophil (%)	62	69	96↑	83↑
Lymphocytes (%)	30	19 ↓	2↓	10↓
PCV (%)	28.90↓	30.00↓	29.10↓	26.70↓
MCV (fL)	65.20↓	66.50↓	65.90↓	64.10↓
MCH (pg)	21.10↓	21.90↓	21.40↓	20.90↓
TIBC (μg/dL)	196.00↓			
RDW (%)	17.10↑	17.60↑	18.20↑	18.40↑
T. Bili (mg/dL)	0.16↓		1.27↑	
D. Bili (mg/dL)	0.10		0.87↑	
I. Bili (mg/dL)	0.06↓		0.40	
AST (U/L)	19		75	
ALT (U/L)	18		32	
ALP (U/L)	79		112	
Amylase (U/L)	120↑	93	244↑	85
Lipase (U/L)	109	136	2217↑	260
IRON (μg/dL)	10.00↓			
Transferrin (%)	5.10↓			
HbA1c (%)	6.2 ↑			
Vit B12	>2000↑			
PT (s)	11.5	12.30	16.50↑	
INR	1.01	1.02	1.43↑	

HB: hemoglobin, WBC: white blood cells, ESR: erythrocyte sedimentation rate, PCV: packed cell volume, MCV: mean corpuscular volume, MCH: mean corpuscular hemoglobin, TIBC: total iron binding capacity, RDW: red cell distribution width, T. Bili: total bilirubin, D. Bili: direct bilirubin, I. Bili: indirect bilirubin, AST: aspartate aminotransferase, ALT: alanine transaminase, ALP: alkaline phosphatase, HbA1c: glycated hemoglobin, PT: prothrombin time, INR: international normalized ratio.

advised regular follow-up.

### Discussion

In 1958, a gastroenterologist named Jacques Caroli reported a rare congenital disease in France. He said it was "non-obstructive fusiform multifocal segmental dilatation of the intra-hepatic bile ducts".<sup>6</sup> Caroli disease affects more women than men. Family history includes kidney and liver disease due to the link between Caroli disease and autosomal recessive polycystic kidney disease (ARPKD).<sup>6</sup> Patients with Caroli syndrome have shown alterations in the PKHD1 gene related to ARPKD and autosomal dominant polycystic kidney disease (ADPKD).<sup>6</sup> According to researchers, this condition is inherited as an autosomal dominant genetic trait. However, the more severe type of Caroli disease seems to be inherited as an autosomal recessive genetic characteristic.<sup>6</sup> Its signs and symptoms, including hepatomegaly, fever, and intermittent abdominal pain, are usually present as the initial symptoms. Jaundice happens occasionally.

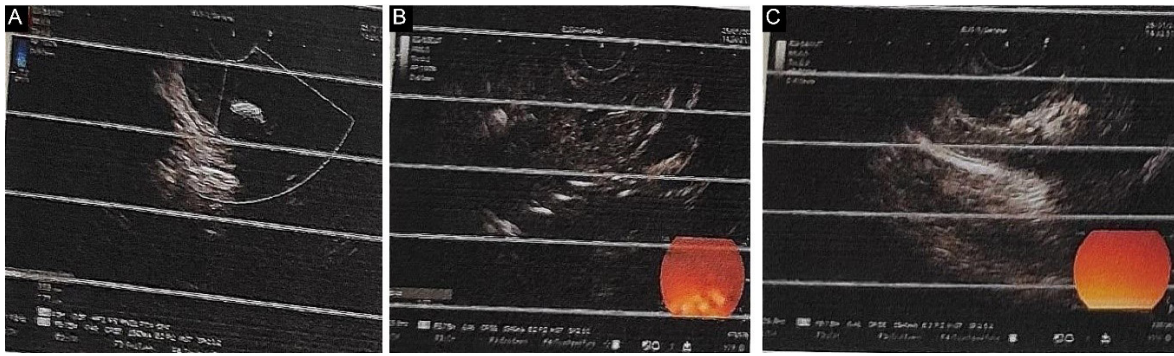


Figure 1. Endoscopic ultrasound report: Caroli's disease with PD calculi

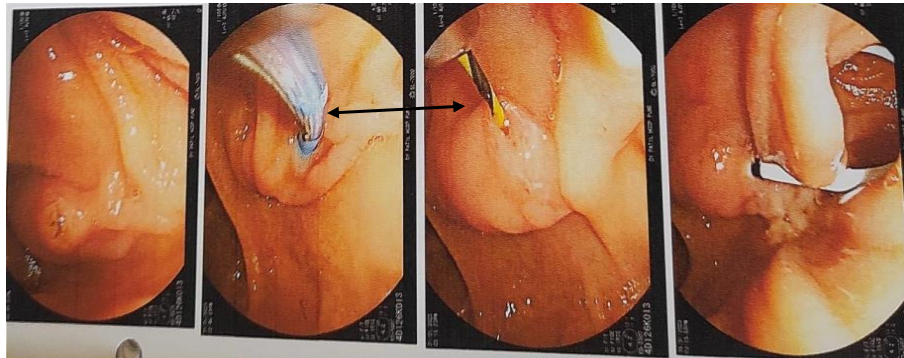


Figure 2. ERCP: Prominent pancreatic duct (PD)

Caroli disease usually develops in association with other conditions such as cholangitis, gallstones, biliary abscess, septicemia, liver cirrhosis, renal failure, and cholangiocarcinoma.<sup>7</sup> Histologically, Caroli disease's main microscopic and macroscopic features are non-obstructive, localized dilatation of the bile ducts, intraductal vascular tracts containing patent portal venous and hepatic arterial channels that traverse the true lumen, and intraluminal bulbar protrusions of the ductal wall.<sup>8</sup> The ability to demonstrate continuity between the cystic lesions and the biliary tree is consequently necessary for diagnosing CD. It can be carried out using imaging tests such as abdominal ultrasonography, computed tomography, isotope scan, ERCP, and MRCP.<sup>9</sup> Caroli disease can be complicated by the formation of liver abscesses, intra and extrahepatic lithiasis, and even cholangiocarcinoma.<sup>8</sup> The treatment of Caroli disease depends on the clinical features and the location of the biliary abnormalities.<sup>8</sup> Appropriate antibiotics for cholangitis and ursodeoxycholic acid therapy to prevent stone formation in case of intrahepatic cholelithiasis.<sup>10</sup> Radiological, endoscopic, and surgical intervention may be required for patients with biliary obstruction, abscess formation, and liver or gallbladder stones. Recurrent cholangitis may have a substantial impact on quality of life. The prognosis depends on the clinical course and the risk of cholangiocarcinoma.<sup>10</sup> As it is a rare genetic disorder, there are no preventive measures. In our case, multiple cystic forms were detected on the MRCP, endoscopic ultrasonography, and abdominal ultrasonography scans [as shown in Figures 1 and 2]. We have identified a dot

sign in our patient. According to lab results, the patient had anemia and elevated amylase levels, indicating acute pancreatitis managed with antibiotics and hydration.

### Conclusion

In conclusion, polycystic kidney disease and various disorders affecting other organ systems may be linked to Caroli disease, an uncommon congenital abnormality of the intrahepatic bile ducts. Caroli disease should be included in the differential diagnosis of epigastric stomach pain despite its extremely low prevalence as well as recurrent cholangitis without risk factors or pertinent family history. Following a clinical suspicion, the diagnosis is always radiologic, with the preferred tests being MRCP and ultrasonography. Instead of the more typical manifestation of recurrent cholangitis, Caroli's illness can also manifest as a chronic, intractable stomach ache. Ursodeoxycholic acid should be used for medical therapy; however, surgical intervention may be beneficial. Despite this, the location and size of cystic dilations, the history of the disease, any complications, and any coexisting conditions all play a significant role in the care strategy that should be tailored to each patient. Early treatments and close follow-ups are necessary since complications from cholangiocarcinoma can be severe and frequent.

### Authors' Contribution

**Conceptualization:** Karishma M Rathi, Priyanka Pingat, Prachi Bansode, Shaili Dongare.

**Data curation:** Prachi Bansode, Shaili Dongare.

**Methodology:** Priyanka Pingat, Prachi Bansode, Shaili Dongare.

**Visualization:** Shaili Dongare, Priyanka Pingat, Prachi Bansode.

**Writing–original draft:** Priyanka Pingat, Shaili Dongare, Prachi Bansode.

**Writing–review & editing:** Prachi Bansode, Shaili Dongare.

#### Competing Interests

The authors declare no conflict of interest related to this work.

#### Ethical Approval

Informed consent was obtained from the patient for publication of this report .

#### Funding

None.

#### References

1. Issar P, Issar SK. Caroli's disease. *Indian J Gastroenterol* 2014;33(5):500. doi: [10.1007/s12664-013-0403-5](https://doi.org/10.1007/s12664-013-0403-5)
2. Sweeney WE, Avner ED. Polycystic kidney disease, autosomal recessive. In: Adam MP, Feldman J, Mirzaa GM, Pagon RA, Wallace SE, Bean LJH, et al, eds. *GeneReviews*®. Seattle, WA: University of Washington; 2001. <https://www.ncbi.nlm.nih.gov/books/NBK1326/>.
3. Tiotia R, Sharma M, Narayani V, Singh S, Dewan V, Deswal S, et al. Atypical presentation of Caroli's syndrome: a case report. *Indian J Case Rep* 2019;5(1):76-8. doi: [10.32677/IJCR.2019.v05.i01.026](https://doi.org/10.32677/IJCR.2019.v05.i01.026)
4. Giovanardi RO. Monolobar Caroli's disease in an adult. Case report. *Hepatogastroenterology* 2003;50(54):2185-7.
5. Ananthakrishnan AN, Saeian K. Caroli's disease: identification and treatment strategy. *Curr Gastroenterol Rep* 2007;9(2):151-5. doi: [10.1007/s11894-007-0010-7](https://doi.org/10.1007/s11894-007-0010-7)
6. Mahakarkar M. Caroli disease. *International Journal of Advances in Nursing Management* 2017;5(4):354-6. doi: [10.5958/2454-2652.2017.00075.0](https://doi.org/10.5958/2454-2652.2017.00075.0)
7. Seddik H, Basr H, Aitbihi B, Adioui T, Massit H, Benkirane A. Monolobar Caroli's disease: report of three cases. *Int J Gastroenterol Hepatol Transpl Nutr* 2017;2(1):23-5.
8. Yonem O, Bayraktar Y. Clinical characteristics of Caroli's disease. *World J Gastroenterol* 2007;13(13):1930-3. doi: [10.3748/wjg.v13.i13.1930](https://doi.org/10.3748/wjg.v13.i13.1930)
9. Yao X, Ao W, Fang J, Mao G, Chen C, Yu L, et al. Imaging manifestations of Caroli disease with autosomal recessive polycystic kidney disease: a case report and literature review. *BMC Pregnancy Childbirth* 2021;21(1):294. doi: [10.1186/s12884-021-03768-8](https://doi.org/10.1186/s12884-021-03768-8)
10. Tajik P, Goudarzian AH. Caroli syndrome in a child: a case report. *Case Rep Clin Pract* 2019;4(3):89-93. doi: [10.18502/crcp.v4i3.1716](https://doi.org/10.18502/crcp.v4i3.1716)