



Original Article

Etiological Profile of Lower Gastrointestinal Bleeding in Children and Adolescents from Kashmir; A Tale of 5 Years

Ishaq Malik^{1*}, Abdus Sami¹, Waseem Yousuf¹, Syed Tariq¹, Shadan Jan¹, Tabish Niyaz¹¹Department of Pediatrics Government Medical College Srinagar Kashmir, India**Abstract**

Background: Lower gut bleeding is an alarming sign among caregivers. Determining the etiology is of utmost importance for further management. This is the first study conducted in northernmost India.

Methods: This cross-sectional study was conducted at the Department of Pediatrics, Government Medical College, Srinagar. This study aimed to describe the etiology of lower gastrointestinal bleeding in the age group of 1-18 years over the past 5 years from June 2017 to June 2022.

Results: A total of 310 children presented with hematochezia (53.5%), blood mixed with loose stools for > 2 weeks (39.3%), melena (1.9%), and occult blood in stools (0.3%). The mean age was 5.12 years. The age group of 1-6 years was 73.5%. The most common findings were rectosigmoid polyps n=104 (33.5%), anal fissure n=47 (15.1%), lymphoid nodular hyperplasia (LNH) n=38 (12.2%), trichuris dysentery syndrome n=30 (9.7%), cow's milk protein allergy n=27 (8.7%), non-specific colitis n=18 (5.8%), solitary rectal ulcer syndrome n=14 (4.5%), inflammatory bowel disease n=6 (1.9%), intestinal tuberculosis n=3 (0.9%), duodenal dieulafof lesion 1 (0.3%), and blue bleb nevus rubber syndrome n=1 (0.3%). 21 patients had a normal colonoscopy. The colonoscopy yield was 93.3%. Among the colonoscopy-negative patients, 6 (1.6%) had Meckel's diverticulum, and 1 (0.3%) had a duodenal dieulafof lesion.

Conclusion: Lower GI bleeding most commonly presents as hematochezia, and the most common cause is a rectosigmoid polyp. Colonoscopy is the procedure of choice to evaluate the etiology of lower GI bleeding. Anal fissures, LNH, *Trichuris trichiura*, and cow's milk protein allergy are other common causes of lower gut bleeding in Kashmir, northernmost India.

Keywords: Lower gastrointestinal bleeding, Rectosigmoid polyps, Trichuris dysentery syndrome, Colonoscopy

Cite this article as: Malik I, Sami A, Yousuf W, Tariq S, Jan S, Niyaz T. Etiological profile of lower gastrointestinal bleeding in children and adolescents from Kashmir; a tale of 5 years. *Middle East J Dig Dis* 2023;15(3):180-184. doi: 10.34172/mejdd.2023.341.

Received: December 19, 2022, **Accepted:** June 3, 2023, **ePublished:** July 30, 2023

Introduction

Lower gastrointestinal (GI) bleeding is bleeding from the gastrointestinal tract distal to the ligament of Treitz and usually presents with the passage of bright red blood (hematochezia) or blood clots per rectum, loose stools mixed with blood, or chronic anemia with positive stool occult blood with normal upper gut endoscopy.¹ The reported incidence in children in Western literature is approximately 20 in 100 000 per year.² Lower GI bleeding is one of the common complaints encountered by pediatric specialists.³

Colonoscopy is the procedure of choice for investigating the etiology of lower GI bleeding.⁴ Determining the cause of bleeding is important for appropriate management of affected children. No such study has been undertaken in this northernmost part of India, Kashmir. Here, we describe the etiology of lower GI bleeding in children and adolescents.

Material and Methods

This cross-sectional study included all patients with lower GI bleeding from June 2017 to June 2022 at the Post-Graduate Department of Pediatrics, Government Medical

College, Srinagar. This study aimed to describe the etiology of lower GI bleeding in the 1-18 years age group.

Inclusion criteria: All patients aged 1-18 years who presented with lower GI bleeding were included. Children less than one year, those with acute dysentery or intussusception, and those who did not give consent were excluded. Lower GI bleeding was defined as the passage of fresh blood in stools, the passage of loose mucoid stools with blood for more than two weeks, melena, or positive stool occult blood with normal upper gut endoscopy.⁴ All patients presenting with lower GI bleeding received an initial assessment and resuscitation, followed by a detailed history and physical examination. After the stabilization of the patients, baseline investigations were performed in all patients, including a complete hemogram, coagulation profile, blood grouping, and typing. Colonoscopy was performed for diagnostic evaluation after proper bowel preparation using PEG solution at a dose of 4000 ml/1.73 m² given over one day or two days in patients less than 4 years with a liquid-only diet during preparation.^{4,5} Patients were kept nil per oral 6 hours prior to the procedure. Fujinon Model: EC-530LP pediatric colonoscope was used. The procedure was performed under sedation using



*Corresponding Author: Ishaq Malik, Email: sfsyedfarheen@gmail.com

© 2023 The Author(s). This work is published by Middle East Journal of Digestive Diseases as an open access article distributed under the terms of the Creative Commons Attribution License (<http://creativecommons.org/licenses/by/4.0/>), which permits unrestricted use, distribution, and reproduction in any medium, provided the original work is properly cited.

intravenous midazolam and ketamine at doses of 0.1 mg/kg and 2 mg/kg, respectively, and repeated when needed. Monitoring was performed using vital measurements and pulse oximetry.⁴ Multiple mucosal biopsies were taken in patients with features of inflammation. Endoscopic management was done where feasible and indicated, like polypectomy or argon plasma photocoagulation.

Results

In total, 310 patients were included in the final analysis. The mean age of presentation with lower GI bleed in our study was 5.12 years, with a range of 1-18 years. The age group of 1-6 years (73.5%) dominated the presentation. Males: female ratio was 0.9:1. The baseline characteristics of the patients are shown in Table 1. The most common clinical presentation was haematochezia.

The colonoscopic and histopathological findings are presented in Tables 2 and 3.

The etiological factors of lower GI bleeding at our center are summarized in Table 4.

Discussion

Bleeding from the lower gut often makes the parents anxious. Most often, the cause is benign. Determining the cause and proper management will ease parental anxiety and reduce frequent visits to healthcare facilities. The

age group of 1-6 years dominates the scene. The most common presentation in our study was hematochezia, followed by blood mixed with loose stool. The age group and presentation were consistent with those of other studies.^{6,7,8}

The most common cause (33.5%) of lower GI bleeding in our study was rectosigmoid polyp (n=104). Polyps are the most common cause of lower gut bleeding in children in India, Pakistan, and Iran.⁴ Polyps are the most common cause of lower gut bleeding in children from India, Pakistan, and Iran.⁴ 84 patients (81%) had solitary and 20 patients (19%) had multiple. Polyps were located in the rectosigmoid in 95% (n=99) of patients. Juvenile polyps were the most common histological type in 97% of patients (n=101). Poddar et al. reported 85% of the polyps were in rectosigmoid, and 93% were juvenile.⁶ Consistent results were reported by Deeb et al.⁹ Syndromic (one each of juvenile polyposis syndrome and hamartomatous/neuroganglioma polyposis syndrome) patients had polyps of the stomach, duodenum, and ileocolon (Figure 1). Anal fissure was the second most common cause of lower GI bleeding (15.1%, n=47) in our study. A study from Central India attributed anal fissures to 21% of cases.⁷

Table 1. Patient characteristics

Variables	
Total no. of patients	N=310
Age	Age group 1-17 years
	Mean age 5.12 years
Gender	Males 151 (49%)
	Females 159 (51%)
Clinical presentation	Haematochezia (53.5%)
	Blood mixed with loose stools (39.3%)
	Melena with normal upper GI endoscopy (1.9%)
	Occult blood in stools (0.3%)
	Blue blebs on skin (0.3%)
Associated features	Abdominal pain (24%)
	Constipation (16.4%)
	Weight loss (4.1%)
	Fever (1.6%)

Table 2. Colonoscopy findings

Colonoscopic findings	Number of patients
Polyp	104 (33.5%)
Ulceration/hyperemia	87 (28%)
Mucosal nodules	38 (12.2%)
Anal fissure	47 (15.1%)
<i>Trichuris trichiura</i>	30 (9.7%)
Blue blebs (blue bleb nevus rubber syndrome)	1 (0.3%)
Normal findings	21 (6.7%)

Table 3. Histopathological diagnosis

Histopathological finding	No of patients
Juvenile polyp	101
Hamartomatous/neuroganglioma polyps	1
Villous adenoma	1
SRUS polyp	1
Lymphonodular hyperplasia of the colon	38
Ulcerative colitis	4
Crohn's disease	2
Ileocecal tuberculosis	3
Non-specific colitis	18
Solitary rectal ulcer	14
Cow milk protein allergy	27

Table 4. Etiology of lower GI bleeding

Causes of lower GI bleeding	No of patients (n=310)	Percent
Polyps	104	33.5%
Anal fissure	47	15.1%
Lymphonodular hyperplasia	38	12.2%
Trichuris dysentery syndrome	30	9.7%
Cow milk protein allergy	27	8.7%
Non-specific colitis	18	5.8%
Solitary rectal ulcer syndrome	14	4.5%
Inflammatory bowel disease	6	1.9%
Meckel's diverticulum	6	1.9%
Intestinal tuberculosis	3	0.9%
Dieulafoy lesion of duodenum	1	0.3%
Blue bleb nevus rubber syndrome	1	0.3%
Meckel's diverticulum	6	1.9%

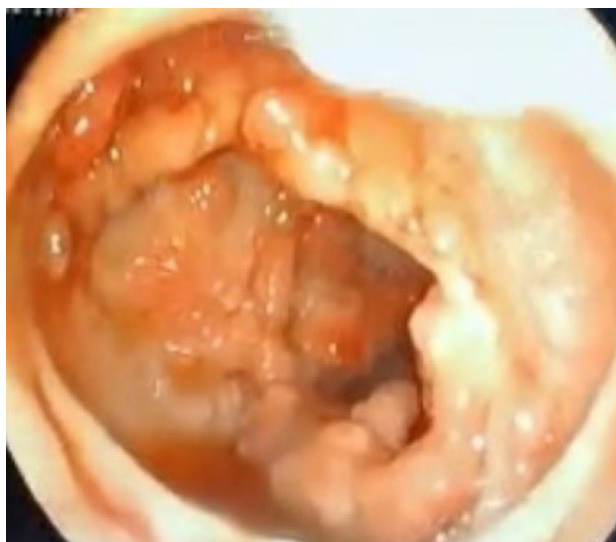

Figure 1. Neuroangliomas in hamartomatous/suspected Cowden's polyposis syndrome

The third most common cause was lymphoid nodular hyperplasia (LNH) in 12.2% (n=38) of patients. It is a benign condition that may involve any part of the gut and is caused by non-specific responses to different stimuli. Zahmatkeshan et al reported LNH in 15.2% of pediatric patients as a cause of gastrointestinal bleeding.⁸ *Trichiura trichuris* was responsible for 9.7% (n=30) of the patients with lower GI bleeding. Trichuris dysentery syndrome presents as abdominal pain, bleeding per rectum, and anemia, with or without growth retardation.^{10,11} A prevalence of 27.9% in the pediatric population has been reported in Kashmir.¹² Cow milk protein allergy is a mixed allergic response to cow's milk and presents as irritability, vomiting, abdominal pain, rectal bleeding, and anemia. It is the most common food protein allergy in both infants and children.¹³ The diagnosis was based on colonoscopic findings of aphthous ulcers, lymphonodular hyperplasia in the rectosigmoid, and biopsy demonstrating focal eosinophilic cryptitis (>6 eosinophils/hpf in > two crypts) or eosinophilic proctitis with a response to cow's milk protein exclusion in the diet.¹⁴ Solitary rectal ulcer syndrome is diagnosed based on endoscopic findings of single or multiple ulcers with or without a polypoid appearance and histological findings of fibrosis in the lamina propria, which differentiates it from inflammatory bowel disease.^{15,16} Solitary rectal ulcers contributed 4.7% (n=17) to lower gut bleeding in our study. Consistent findings were reported by Mandhan.¹⁷ Non-specific colitis was present in 5.8% (n=18) of patients. Most patients had mild erythema and aphthous proctitis in the left colon. Biopsy revealed non-specific inflammation without features suggestive of inflammatory bowel disease. Non-specific proctitis in children is an indistinctly described entity, with lesions restricted to the rectosigmoid.^{16,18} Deeb et al attributed non-specific colitis to lower GI bleeding in 24% of pediatric patients.⁹ Inflammatory bowel disease constituted 1.9% (n=6) of the patients with

lower GI disease in our study. Patients with ulcerative colitis had mucosal hyperemia, increased friability, loss of vascularity, and superficial ulcers in the distal colon with histological features of cryptitis, crypt distortion, and inflammatory cell infiltrates. Crohn's disease was diagnosed based on narrowing of the ileocolonic region, cobblestoning in the proximal colon with non-caseating granulomas in the presence of transmural inflammation. Inflammatory bowel disease is a common cause of rectal bleeding in children in the West. This constituted 1.9% of the total rectal bleeding cases in our study.⁴ Intestinal tuberculosis constituted 0.9% of the patients (n=3), with colonoscopic findings of erythema, pseudo-polyp formation, mucosal ulcers, and ileocecal valve deformity (Figure 2). Biopsy showed caseating granulomas, and a gene expert confirmed the diagnosis of intestinal tuberculosis. In an Indian study tuberculosis constituted 3.5% of rectal bleeding cases. In a large series by Yachha et al, Khurana et al, and Bhargava et al, the common causes of lower GI bleeding in children were other than IBD.¹⁹⁻²¹ Blue rubber bleb nevus syndrome (n=1) presents as multifocal, circumscribed, well-demarcated lesions due to venous malformation (Figure 3) throughout the bowel, along with skin blebs.²² Colonoscopy findings were normal in 21 patients (6.7%). The colonoscopic yield in our study was 93.3%. Similar results were reported by Motamed et al²³ in their study.

Patients with negative colonoscopy included 6 patients with Meckel's diverticulum, one patient with a Dieulafoy lesion of the duodenum, and one case of small bowel duplication. Meckel's diverticulum (Figure 2) (n=6) presented with two or more episodes of melena; all were under 6 years of age with hemodynamic compromise because of a rapid fall in hemoglobin requiring blood transfusion. Upper gastrointestinal endoscopy and colonoscopy findings were normal. Meckel's scan was positive in only two patients, and the diagnosis was confirmed by laparoscopy. In a large series, the most common complication of Meckel's diverticulum was lower GI bleeding, 40% in a large series.²⁴ One of the patients presented with massive upper gastrointestinal bleeding with hemodynamic compromise and normal initial upper endoscopy and colonoscopy. Repeat upper endoscopy revealed a bleeding dieulafoy lesion that was managed using a hemoclip. Dieulafoy lesions are submucosal vessels that, instead of tapering directly to the submucosa, bleed upon breach of the mucosa with torrential bleed.²²

A limitation of this study is that it was a single-center study. This is one of the many tertiary care hospitals available in this region, and different etiologies might have been presented to other centers. A multicenter study from this region would definitely provide the exact proportion.

In conclusion, most causes of lower gastrointestinal bleeding in children are benign, and the most common mode of presentation is hematochezia. The most important investigation is colonoscopy, and the most

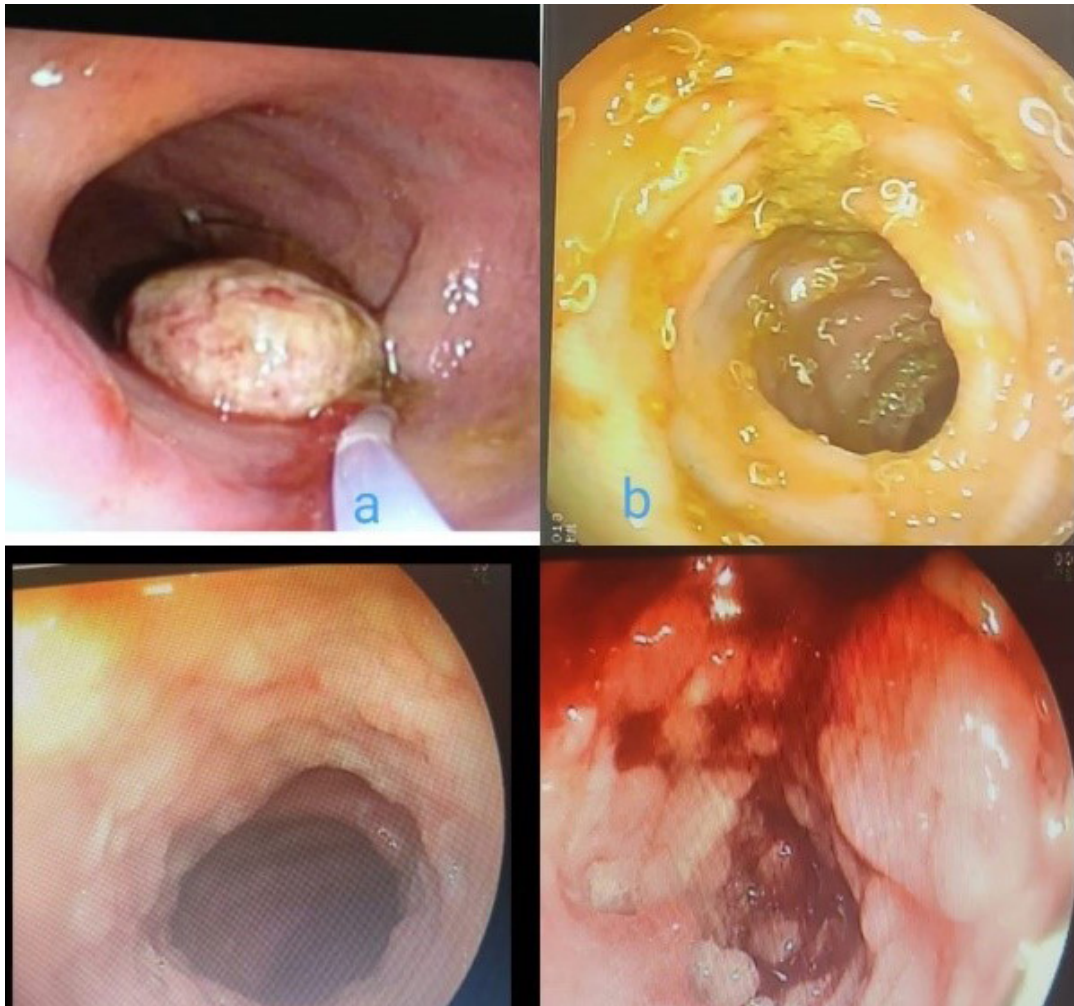


Figure 2. (a) rectal polyp with snare in place (b) *Trichuris trichiura* in left colon (c) narrowing, loss of vascularity in Crohn's disease (d) tuberculosis in ileocecal region

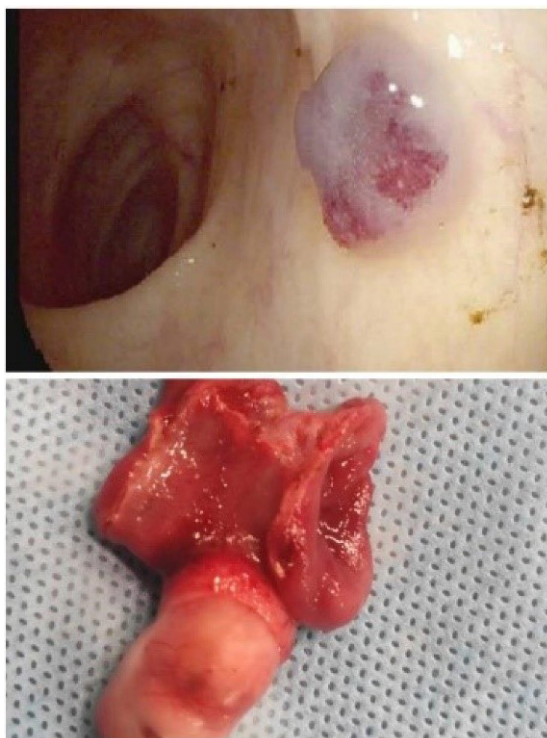


Figure 3. The upper part shows the colonic bleb of the BRBNS. The lower portion shows an excised Meckel's diverticulum

common cause of lower gastrointestinal bleeding is colorectal polyp. Anal fissure, LNH of the colon, *Trichuris trichiura*, and cow milk protein allergy, in descending order, constitute the other causes of lower GI bleeding in children from Kashmir, northernmost India.

Authors' Contribution

Conceptualization: Ishaq Malik.

Data curation: Shadan Muzafar, Tabish Niyaz.

Formal analysis: Abdus Sami.

Writing—original draft: Ishaq Malik.

Writing—review & editing: Abdus Sami.

Competing Interests

The authors declare no conflict of interest related to this work.

Ethical Approval

The study was approved by institutional ethical committee with reference no: 137/ETH/GMC Dated: 20-10-2018. Informed consent was obtained from parents and guardians.

References

1. Iacono G, Ravelli A, Di Prima L, Scalici C, Bolognini S, Chiappa S, et al. Colonic lymphoid nodular hyperplasia in children: relationship to food hypersensitivity. *Clin Gastroenterol Hepatol* 2007;5(3):361-6. doi: [10.1016/j.cgh.2006.12.010](https://doi.org/10.1016/j.cgh.2006.12.010)
2. Clarke G, Robb A, Sugarman I, McCallion WA. Investigating painless rectal bleeding--is there scope for improvement?

- J Pediatr Surg* 2005;40(12):1920-2. doi: [10.1016/j.jpedsurg.2005.08.007](https://doi.org/10.1016/j.jpedsurg.2005.08.007)
3. Saleem S, Dab RH, Akram M. Lower GIT bleeding: role of sigmoidoscopy. *Prof Med J* 2005;12(2):170-5.
 4. Sharma B, Sharma R, Bodh V, Sharma S, Sood A, Sharma R, et al. Chronic lower gastrointestinal bleeding: etiological profile and role of colonoscopy among children from sub-Himalayan ranges of North India. *J Dig Endosc* 2018;9(3):109-13. doi: [10.4103/jde.JDE_33_18](https://doi.org/10.4103/jde.JDE_33_18)
 5. Tripathi PR, Poddar U, Yachha SK, Sarma MS, Srivastava A. Efficacy of single-versus split-dose polyethylene glycol for colonic preparation in children: a randomized control study. *J Pediatr Gastroenterol Nutr* 2020;70(1):e1-e6. doi: [10.1097/mpg.0000000000002511](https://doi.org/10.1097/mpg.0000000000002511)
 6. Poddar U, Thapa BR, Vaiphei K, Singh K. Colonic polyps: experience of 236 Indian children. *Am J Gastroenterol* 1998;93(4):619-22. doi: [10.1111/j.1572-0241.1998.176.b.x](https://doi.org/10.1111/j.1572-0241.1998.176.b.x)
 7. Bhaduria N, Dubey SR, Mittal P, Arya AK, Singh RP. Clinico-etiological pattern of lower gastrointestinal bleeding in children (5-18 years age group) at a tertiary care center in central India. *Indian J Child Health* 2016;3(4):290-2. doi: [10.32677/IJCH.2016.v03.i04.004](https://doi.org/10.32677/IJCH.2016.v03.i04.004).
 8. Zahmatkeshan M, Fallahzadeh E, Najib K, Geramizadeh B, Haghghat M, Imanieh MH. Etiology of lower gastrointestinal bleeding in children: a single center experience from southern Iran. *Middle East J Dig Dis* 2012;4(4):216-23.
 9. Deeb MM, El-Zayat RS, Abo El-Khair HA. Colonoscopic findings in children with lower gastrointestinal bleeding. *Menoufia Med J* 2016;29(2):247-51. doi: [10.4103/1110-2098.192425](https://doi.org/10.4103/1110-2098.192425)
 10. Zeehaida M, Zueter A, Zairi NZ, Zunulhisham S. Trichuris dysentery syndrome: Do we learn enough from case studies? *Trop Biomed* 2015;32(3):545-50.
 11. Khuroo MS, Khuroo MS, Khuroo NS. Trichuris dysentery syndrome: a common cause of chronic iron deficiency anemia in adults in an endemic area (with videos). *Gastrointest Endosc* 2010;71(1):200-4. doi: [10.1016/j.gie.2009.08.002](https://doi.org/10.1016/j.gie.2009.08.002)
 12. Wani SA, Ahmad F, Zargar SA, Dar PA, Dar ZA, Jan TR. Intestinal helminths in a population of children from the Kashmir valley, India. *J Helminthol* 2008;82(4):313-7. doi: [10.1017/s0022149x08019792](https://doi.org/10.1017/s0022149x08019792)
 13. Rona RJ, Keil T, Summers C, Gislason D, Zuidmeer L, Sodergren E, et al. The prevalence of food allergy: a meta-analysis. *J Allergy Clin Immunol* 2007;120(3):638-46. doi: [10.1016/j.jaci.2007.05.026](https://doi.org/10.1016/j.jaci.2007.05.026)
 14. Poddar U, Yachha SK, Krishnani N, Srivastava A. Cow's milk protein allergy: an entity for recognition in developing countries. *J Gastroenterol Hepatol* 2010;25(1):178-82. doi: [10.1111/j.1440-1746.2009.06017.x](https://doi.org/10.1111/j.1440-1746.2009.06017.x)
 15. Figueroa-Colon R, Younoszai MK, Mitros FA. Solitary ulcer syndrome of the rectum in children. *J Pediatr Gastroenterol Nutr* 1989;8(3):408-12. doi: [10.1097/00005176-198904000-00027](https://doi.org/10.1097/00005176-198904000-00027)
 16. Tjandra JJ, Fazio VW, Petras RE, Lavery IC, Oakley JR, Milsom JW, et al. Clinical and pathologic factors associated with delayed diagnosis in solitary rectal ulcer syndrome. *Dis Colon Rectum* 1993;36(2):146-53. doi: [10.1007/bf02051170](https://doi.org/10.1007/bf02051170)
 17. Mandhan P. Sigmoidoscopy in children with chronic lower gastrointestinal bleeding. *J Paediatr Child Health* 2004;40(7):365-8. doi: [10.1111/j.1440-1754.2004.00403.x](https://doi.org/10.1111/j.1440-1754.2004.00403.x)
 18. Earnest D, Sleisenger M. Other diseases of colon and rectum. In: Sleisenger M, Fordtran J, eds. *Gastrointestinal Disease*. Philadelphia: WB Saunders; 1975. p. 1534-5.
 19. Yachha SK, Khanduri A, Sharma BC, Kumar M. Gastrointestinal bleeding in children. *J Gastroenterol Hepatol* 1996;11(10):903-7.
 20. Khurana AK, Saraya A, Jain N, Chandra M, Kulshreshtha R. Profile of lower gastrointestinal bleeding in children from a tropical country. *Trop Gastroenterol* 1998;19(2):70-1.
 21. Bhargava DK, Rai RR, Dasarathy S, Chopra P. Colonoscopy for unexplained lower gastrointestinal bleeding in a tropical country. *Trop Gastroenterol* 1995;16(1):59-63.
 22. Sahn B, Bitton S. Lower gastrointestinal bleeding in children. *Gastrointest Endosc Clin N Am* 2016;26(1):75-98. doi: [10.1016/j.giec.2015.08.007](https://doi.org/10.1016/j.giec.2015.08.007)
 23. Motamed F, Najafi Sani M, Khodadad A, Fallahi G, Farahmand F, Sobhani M. Colonoscopic findings in children with lower gastrointestinal bleeding. *Govareh* 2012;13(1):54-7.
 24. Lin XK, Huang XZ, Bao XZ, Zheng N, Xia QZ, Chen CD. Clinical characteristics of Meckel diverticulum in children: A retrospective review of a 15-year single-center experience. *Medicine (Baltimore)* 2017;96(32):e7760. doi: [10.1097/md.00000000000007760](https://doi.org/10.1097/md.00000000000007760)