



Case Report

Whipple's Disease; An Overlooked Diagnosis

Kerollos Motwade N. Kerollos^{1*}, Bahaa Osman Taha²

¹Loyola University Medical Center, Illinois, USA

²Assiut University Hospitals, Assiut, Egypt

Abstract

Whipple disease is a rare multisystem inflammatory disease. Because fewer than 1000 reported cases have been described, clinical experience with this disorder is sparse. We are reporting a case of a 46-year-old man who presented with fever, weight loss, and polyarthralgia for 2 months, and 1 month of diarrhea. The patient was thoroughly investigated for collagen diseases and COVID-19, with no definite diagnosis. A therapeutic trial by immunosuppressive drugs provided partial remission followed by a marked rebound of the symptoms. His occult blood in stool was positive and subsequent upper endoscopy with proximal small intestinal biopsies showed the pathological features of Whipple's disease. The patient showed a dramatic improvement following treatment with ceftriaxone and trimethoprim-sulfamethoxazole. Despite the rarity of Whipple's disease, its course mimics many rheumatological diseases, inflammatory bowel disease, and COVID-19 disease. It should always be a part of the differential diagnosis of obscure polyarthralgia and chronic diarrhea.

Keywords: Whipple disease, Malabsorption syndrome, COVID-19

Cite this article as: Motwade N. Kerollos K, Osman Taha B. Whipple's disease; an overlooked diagnosis. *Middle East J Dig Dis* 2023;15(2):136-138. doi: 10.34172/mejdd.2023.333.

Received: June 20, 2022, **Accepted:** January 8, 2023, **ePublished:** April 30, 2023

Introduction

Whipple's disease is an uncommon bacterial disease. The clinical manifestations of the disease are caused by the infiltration of the various body tissues by a gram-positive bacterium, *Tropheryma whippeli*. It is a systemic disease including malabsorption syndrome with small intestine involvement. The disease also affects the joints, central nervous system, and cardiovascular system. Due to its rarity, therapeutic trials for other diseases with immunosuppressants may obscure the diagnosis for some time and Whipple's disease is ignored, initially, in the differential diagnosis of chronic polyarthralgia, and chronic diarrhea and our case is an example.

Case Report

A 46-year-old man presented with polyarthralgia involving the large joints (knees, ankles, and shoulders) for 3 months. The patient also had developed chronic diarrhea for one month; watery in nature, 4-5 times per day, not related to a certain food, did not wake the patient at night, and was associated with fever, and significant weight loss (10 kg).

These symptoms were severe enough to leave the patient bedridden and abandon his work as a teacher. On physical examination, he had a fever of 38.3°C, regular tachycardia of 120 bpm, blood pressure of 100/70 mm Hg, and respiratory rate of 22/m. His capillary oxygen saturation was 94%.

He had a cachectic appearance, but the examination of the systems was unremarkable with no joint deformity or

lymphadenopathy.

The patient was on an overseas trip to a country where COVID-19 cases were high, and due to his symptoms, which mimic COVID-19 disease, he was sent into isolation and COVID-19 PCR was done twice excluding the infection. His lab work included full blood count, stool examination, inflammatory markers, comprehensive metabolic panel, thyroid function tests, celiac disease serology, HIV screening, and Brucella antibodies. This extensive workup showed normocytic normochromic anemia (Hb 8 g/dL), positive occult blood in stool, and raised C-reactive protein (CRP) of 28 with normal erythrocyte sedimentation rate (ESR). Moreover, he was investigated for collagen diseases where antinuclear antibodies (ANA), anti-double-stranded deoxyribonucleic acid antibodies (dsDNA Abs), antinuclear ribonucleoprotein (anti-RNP), cyclic citrullinated peptide antibodies (anti-CCP), and antineutrophilic cytoplasmic antibodies (ANCA) were all negative.

Abdominal imaging including ultrasound and multislice computed tomography with intravenous (IV) contrast revealed mild hepatosplenomegaly. Before showing up at our tertiary gastroenterology center, the patient was prescribed immunosuppressive drugs (prednisolone and azathioprine) for undifferentiated connective tissue disease, he had partial improvement for 2 weeks and his fever subsided. This was followed by a rebound of his symptoms, which led to the cessation of the treatment.

At our center, we performed upper endoscopy with proximal small intestine biopsies, which were examined



*Corresponding Author: Kerollos Motwade N. Kerollos, Email: Kerollos_Kerollos@med.aun.edu.eg

© 2023 The Author(s). This work is published by Middle East Journal of Digestive Diseases as an open access article distributed under the terms of the Creative Commons Attribution License (<http://creativecommons.org/licenses/by/4.0/>), which permits unrestricted use, distribution, and reproduction in any medium, provided the original work is properly cited.

using Giemsa stain (Figure 1) and periodic acid-Schiff (PAS) stain (Figure 2).

The tissue biopsy stained positive for PAS and showed histiocytes with diastase resistance positive granules; a result that was in favor of Whipple's disease diagnosis. Intravenous ceftriaxone 2 g/d for 14 days was started for the patient, then trimethoprim-sulfamethoxazole 800/160 mg was prescribed as an outpatient treatment.

Follow-up at a 3-month interval for one year has shown dramatic improvement in the patient's symptoms with the restoration of his functional capacity.

Discussion

Tropheryma whippeli may be a ubiquitous gram-positive microorganism that is rarely related to symptomatic disease, namely, Whipple's disease.¹ *T. whippeli* may be a commensal organism and not an obligate pathogen. The incidence of Whipple's disease has been estimated at about 0.5 to 1/1 000 000 people.² The way of transmission may involve the passage of the bacterial agent from the environment into the body through the digestive tract, followed by fecal-oral transmission. However, person-to-person transmission through the oral-oral route cannot be ruled out.³ Whipple's disease often ends up in chronic seronegative arthritis that would be often misdiagnosed.^{4,5} Interestingly, 1.58% of patients with unexplained arthritis and no other evidence of Whipple's disease were positive for *T. whippeli*.⁶ Articular involvement often characterizes




Figure 1. Biopsy specimen of the duodenal mucosa with Giemsa stain

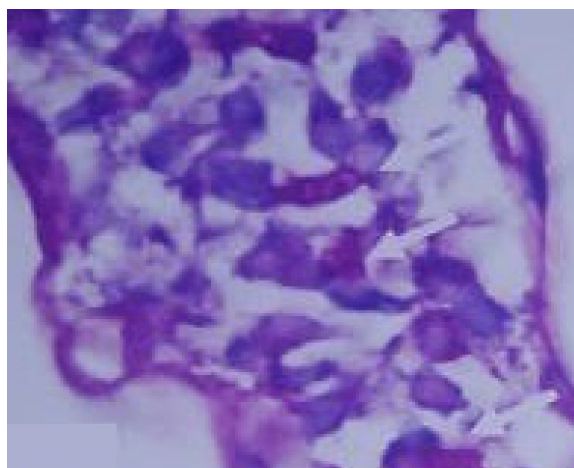


Figure 2. Biopsy specimen of the duodenal mucosa. The stroma is infiltrated with macrophages having a coarse granular intracytoplasmic PAS positivity

the onset of Whipple's disease. The mean solar time from the event of articular symptoms to the diagnosis is nearly 7 years,⁷ but there are some reports focusing the eye on the very late diagnosis of Whipple's disease, within the absence of gastrointestinal symptoms.^{8,9} Arthritis has been reported in 41%-61% of cases.⁷ All patients had increased CRP, while rheumatoid factor and anti-CCP were absent, and everyone was initially misclassified as suffering from seronegative rheumatoid arthritis. Six patients received disease-modifying antirheumatic drugs (DMARD) treatment consisting of methotrexate and/or leflunomide, and three were also treated with a minimum of one DMARD. Most patients showed an inadequate response. A recent literature search of 19 studies reported the utilization of immunosuppressive drugs, particularly therapy with TNF inhibitors, before the diagnosis in 41 patients with Whipple's disease.³ As arthritis may precede the diagnosis of Whipple's disease by a few years, a relevant percentage (up to 50% in some reports) of patients is treated with immunomodulatory drugs or with biologics. Histological detection of macrophage-containing PAS-positive granules within the duodenum lamina propria is considered the quality diagnostic method.¹ Antibiotic therapy usually promptly provides improvement within the clinical and laboratory abnormalities,¹⁰ but it is of great importance to continue the treatment for a minimum of 2 years or perhaps preferably throughout life.^{11,12}

Authors' Contribution

Conceptualization: Bahaa Osman Taha.

Data curation: Kerollos Motwade N. Kerollos.

Formal analysis: Kerollos Motwade N. Kerollos.

Investigation: Bahaa Osman Taha.

Methodology: Kerollos Motwade N. Kerollos.

Project administration: Bahaa Osman Taha.

Resources: Kerollos Motwade N. Kerollos.

Supervision: Bahaa Osman Taha.

Validation: Bahaa Osman Taha.

Visualization: Bahaa Osman Taha.

Writing—original draft: Kerollos Motwade N. Kerollos.

Writing—review & editing: Kerollos Motwade N. Kerollos.

Competing Interests

The authors declare no conflict of interest related to this work.

Ethical Approval

Consent for publication (verbal) was obtained from the patient. Privacy and Confidentiality were maintained.

References

1. Marth T, Moos V, Müller C, Biagi F, Schneider T. *Tropheryma whippeli* infection and Whipple's disease. *Lancet Infect Dis* 2016;16(3):e13-22. doi: 10.1016/s1473-3099(15)00537-x
2. Biagi F, Balduzzi D, Delvino P, Schieppati A, Klersy C, Corazza GR. Prevalence of Whipple's disease in north-western Italy. *Eur J Clin Microbiol Infect Dis* 2015;34(7):1347-8. doi: 10.1007/s10096-015-2357-2
3. Várölygi C, Bubán T, Szakáll S, Hargitai Z, Galuska L, Jeney C, et al. Fever of unknown origin with seronegative spondyloarthropathy: an atypical manifestation of Whipple's disease. *Ann Rheum Dis* 2002;61(4):377-8. doi: 10.1136/ard.61.4.377

4. Fenollar F, Puéchal X, Raoult D. Whipple's disease. *N Engl J Med* 2007;356(1):55-66. doi: [10.1056/NEJMra062477](https://doi.org/10.1056/NEJMra062477)
5. Ramos JM, Pasquau F, Galipienso N, Valero B, Navarro A, Martinez A, et al. Whipple's disease diagnosed during anti-tumor necrosis factor alpha treatment: two case reports and review of the literature. *J Med Case Rep* 2015;9:165. doi: [10.1186/s13256-015-0632-6](https://doi.org/10.1186/s13256-015-0632-6)
6. Glaser C, Rieg S, Wiech T, Scholz C, Endres D, Stich O, et al. Whipple's disease mimicking rheumatoid arthritis can cause misdiagnosis and treatment failure. *Orphanet J Rare Dis* 2017;12(1):99. doi: [10.1186/s13023-017-0630-4](https://doi.org/10.1186/s13023-017-0630-4)
7. Puéchal X, Schaeverbeke T, Sibilia J, Saraux A, Poveda JD. Polymerase chain reaction testing for *Tropheryma whippelii* in unexplained isolated cases of arthritis. *Arthritis Rheum* 2002;46(4):1130-2. doi: [10.1002/art.10099](https://doi.org/10.1002/art.10099)
8. Puéchal X. Whipple disease and arthritis. *Curr Opin Rheumatol* 2001;13(1):74-9. doi: [10.1097/00002281-200101000-00012](https://doi.org/10.1097/00002281-200101000-00012)
9. Vanderschueren D, Dequeker J, Geboes K. Whipple's disease in a patient with longstanding seronegative polyarthritis. *Scand J Rheumatol* 1988;17(5):423-6. doi: [10.3109/03009748809105282](https://doi.org/10.3109/03009748809105282)
10. Marth T. Systematic review: Whipple's disease (*Tropheryma whippelii* infection) and its unmasking by tumour necrosis factor inhibitors. *Aliment Pharmacol Ther* 2015;41(8):709-24. doi: [10.1111/apt.13140](https://doi.org/10.1111/apt.13140)
11. Raoult D, Birg ML, La Scola B, Fournier PE, Enea M, Lepidi H, et al. Cultivation of the bacillus of Whipple's disease. *N Engl J Med* 2000;342(9):620-5. doi: [10.1056/nejm200003023420903](https://doi.org/10.1056/nejm200003023420903)
12. Lagier JC, Fenollar F, Lepidi H, Raoult D. Evidence of lifetime susceptibility to *Tropheryma whippelii* in patients with Whipple's disease. *J Antimicrob Chemother* 2011;66(5):1188-9. doi: [10.1093/jac/dkr032](https://doi.org/10.1093/jac/dkr032)