



## Subepithelial Lesion in Bulb with Gastric Outlet Obstruction

Alireza Sharifi<sup>1</sup>, Ahmad Hormati<sup>2,3,\*</sup>, Mohammad Reza Ghadir<sup>4</sup>, Mohammad Bagheri<sup>5</sup>,  
Mahboubeh Afifian<sup>6</sup>

1. General Practitioner, Student Research Committee, Qom University Of Medical Sciences, Qom, Iran
2. Assistant Professor of Gastroenterology and Hepatology Disease Research Center, Qom University of Medical Sciences, Qom, Iran
3. Gastrointestinal and Liver Disease Research Center, Iran University of Medical Sciences, Tehran, Iran
4. Professor of Gastroenterology and Hepatology Disease Research Center, Qom University of Medical Sciences, Qom, Iran
5. Assistant Professor, Digestive Disease Research Center, Shariati Hospital, Tehran University of Medical Sciences, Tehran, Iran
6. MSc. of Health Information Technology, Tehran University of Medical Sciences, Tehran, Iran.

### \* Corresponding Author:

Ahmad Hormati, MD  
Gastroenterology and Hepatology Disease Research Center, Shahid Beheshti Hospital, Qom University of Medical Sciences, Qom, Iran

Tel: + 98 253 6122052  
Fax: + 98 253 6122053  
Email: hormatia@yahoo.com

Received: 14 Jan. 2020  
Accepted: 10 May 2020

Please cite this paper as:

Sharifi AR, Hormati A, Ghadir MR, Bagheri M, Afifian M. Subepithelial Lesion in Bulb with Gastric Outlet Obstruction. *Middle East J Dig Dis* 2020;12:288-291. doi: 10.34172/mejdd.2020.196.

A 63-year-old man is referred to the Emergency Center with complaints of nausea, vomiting, and epigastric pain for 2 weeks. The patient occasionally mentions vomiting after meals and also complains of other symptoms such as bloating, heavy post-meal pain, and pain in the epigastric region with the vomiting. He notes that he has weight lost about 5 kg in the past three months. The pain in the epigastric area was worsened after eating, and following these symptoms, his appetite has decreased.

The patient does not give a history of any particular disease. The patient's vital signs are stable and are as follows:

Blood pressure: 120/100 mm Hg pulse rate: 84/min respiratory rate: 18/min body temperature: 36.5°C

The patient is generally pale in appearance but not icteric. The mucus was dry. In the clinical examinations, her abdomen was fatty, soft, and without distention. The patient had mild tenderness in the epigastric region, and no mass was touched. The rest of his examinations were normal.

The patient's laboratory findings indicate metabolic alkalosis. Table 1 summarizes the most important laboratory findings of the patient:

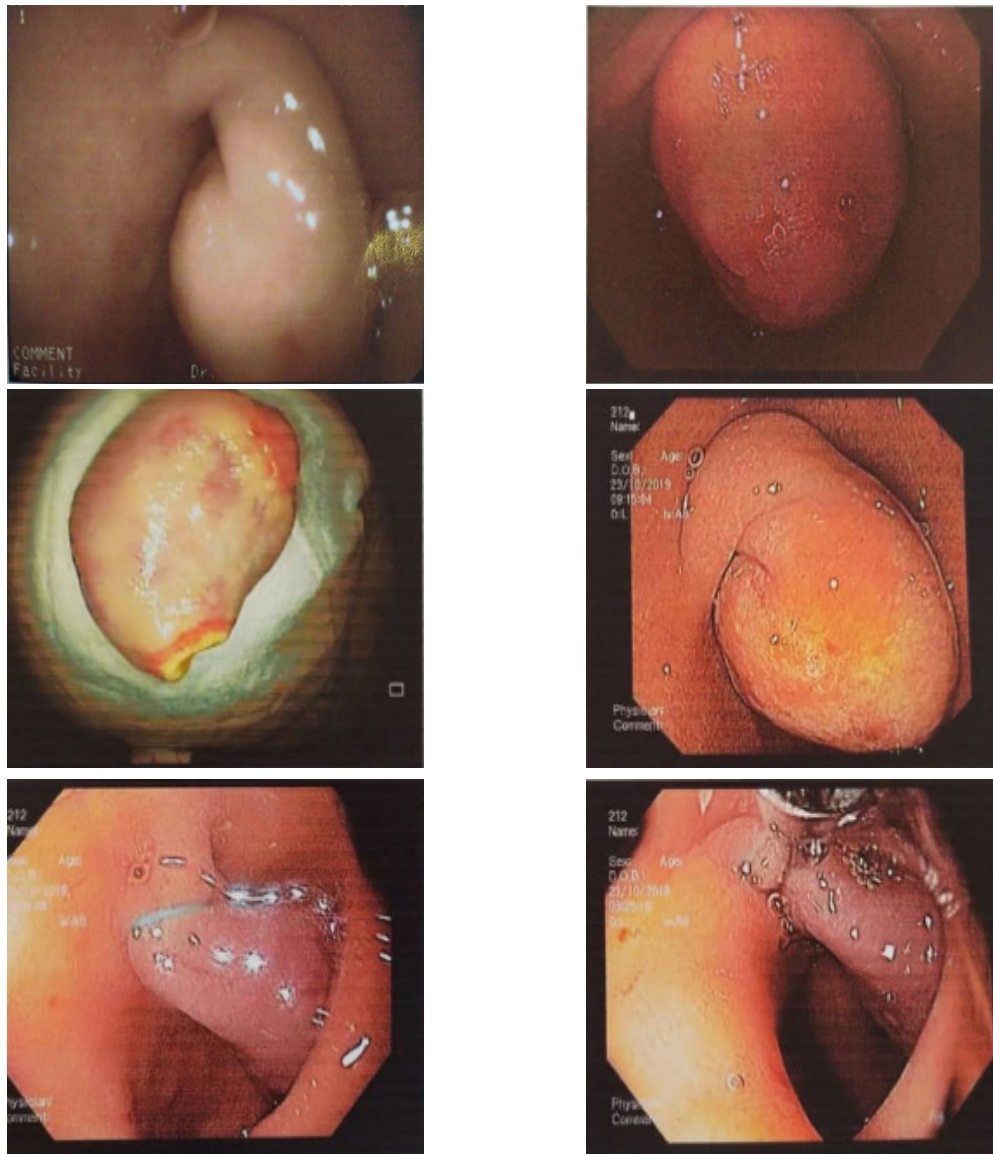
Due to the patient's nausea and vomiting and the diagnosis of the reason, we tried several times to insert the nasogastric (NG) tube, but we failed. The next diagnostic step we took was performing an endoscopy, which revealed the presence of a space lesion in the duodenal bulb that had closed most of the duct. A sample specimen was taken from the lesion and sent for pathological examination.

**Table 1: Laboratory findings on referral time**

Results	Laboratory variables
Hemoglobin	14g/dL
White blood cell (WBC)	11000
Mean Corpuscular Volume (MCV)	78.5%
Creatinine	2 mg/dL
Urea nitrogen	85 mg/dL
Serum Iron	57µg/dL
Transferrin and Iron-binding Capacity (TIBC)	346µg/dL
Total bilirubin	1.8mg/dL
Alanine transaminase (ALT)	23unit/L
Aspartate aminotransferase (AST)	17unit/L



© 2020 The Author(s). This work is published by Middle East Journal of Digestive Diseases as an open access article distributed under the terms of the Creative Commons Attribution License (<https://creativecommons.org/licenses/by-nc/4.0/>). Non-commercial uses of the work are permitted, provided the original work is properly cited.



**Fig.1:** Endoscopic view: Space lesion in the duodenal bulb

### What is your diagnosis?

#### Answer:

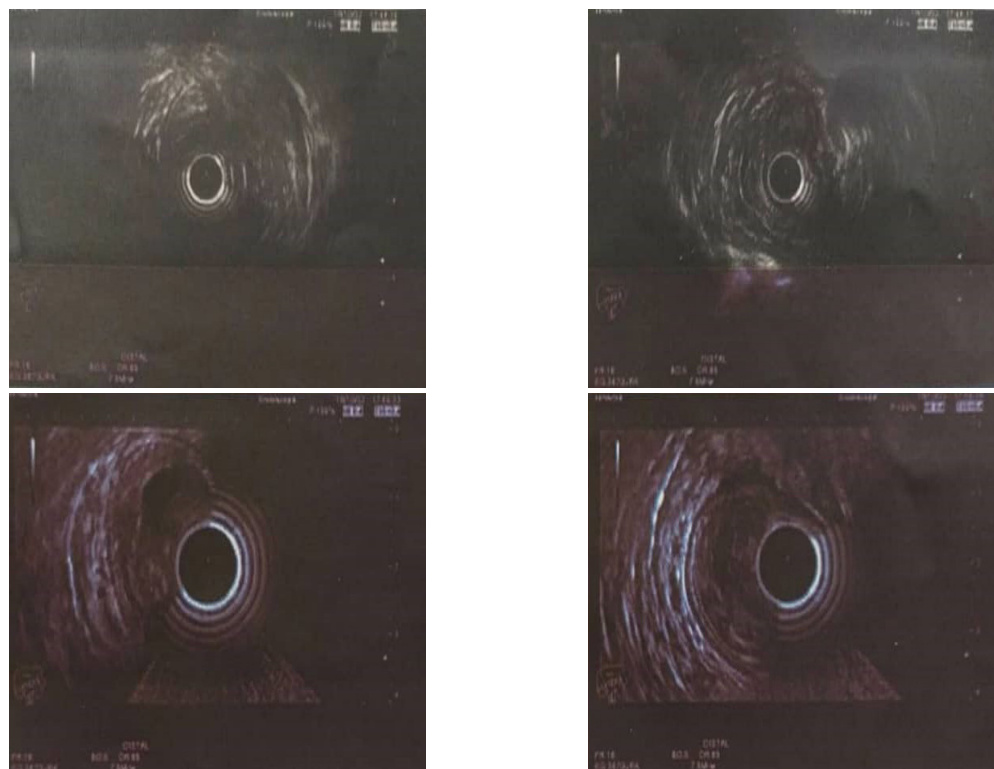
Submucosal lesion of the duodenal bulb with the origin of Bruner's gland hyperplasia

According to the clinical symptoms and laboratory findings of the patient and the result of endoscopy that showed a large space lesion in the gastric outlet (Figure 1), we performed endo-ultrasonography (EUS) for the patient and found a 17 × 23 mm hypoechoic and pedunculated lesion with the origin of layer 2 (muscularis mucosa) in D1 region (Figure 2). A sample was taken

from the lesion and sent for pathology. Based on the EUS results (sub-mucosal lesion in layer 2), differential diagnoses such as carcinoid tumor were also presented to us. But after examining the pathological report of the specimen, we found the origin of the Bruner's glands for this lesion, which suggested hyperplasia of these glands, and the diagnosis of tumor carcinoid was rejected. Then, with the resection of the lesion, the patient's symptoms of nausea and vomiting were also resolved.

### DISCUSSION

The clinical manifestations of abdominal polypoid lesions



**Fig.2:** Endo-ultrasonographic view: Subepithelial lesion from muscularis mucosa layer

can vary. However, most of the affected patients have symptoms of epigastric discomfort, decrease of appetite, vomiting, and nausea.<sup>1</sup> There are various reasons for vomiting after eating and associated digestive symptoms.

Most lesions are less than 1 cm in size,<sup>2</sup> but in our case, it was 17 × 23 mm. Bruner's gland hyperplasia becomes rarer as it gets further from the duodenal bulb: duodenal bulb 57% of cases, the second portion of duodenum 27%, the third portion of duodenum 7%, jejunum 2%, terminal ileum 2%, and 5% are found in the pylorus.<sup>3</sup> Due to the origin of the disease in our case, which was determined after pathological examination and also because of its size, it worth reporting as an unusual and rare case. In our case, because the lesion was pedunculated, intussusception of the lesion into the stomach resulted in symptoms of gastric outlet obstruction (GOO). GOO is a clinical and pathophysiological complication of the process of malignant and benign diseases that leads to mechanical GOO. Until 1970, peptic ulcer disease (PUD) was the most common cause of GOO.<sup>4</sup> But recently, the rate has dropped for this reason.<sup>5</sup> GOO includes obstruction within the gastric-pyloric area or inside the bulb segments

and behind the duodenal bulb. Benign GOO has a variety of causes, including NSAIDs using, helicobacter pylori inflammation, chronic pancreatitis, Crohn's disease, and anastomotic stenosis.<sup>6</sup>

It should be noted that, generally, residual malignancy is the most common cause of GOO worldwide.<sup>7</sup> In our case, after the pathological examination of the specimen, the diagnosis of malignancy was rejected, and Bruner's gland hyperplasia was confirmed.

#### ETHICAL APPROVAL

There is nothing to be declared.

#### CONFLICT OF INTEREST

The authors declare no conflict of interest related to this work.

#### REFERENCES

1. Brooks GS, Frost ES, Wesselhoeft C. Prolapsed hyperplastic gastric polyp causing gastric outlet obstruction, hypergastrinemia, and hematemesis in an infant. *J Pediatr Surg* 1992;**27**:1537-8. doi: 10.1016/0022-3468(92)90498-v.
2. Höchter W, Weingart J, Seib H, Ottenjann R. Duodenal

- polyps. Incidence, histologic substrate and significance. *Dtsch Med Wochenschr* 1984;**109**:1183-6. doi: 10.1055/s-2008-1069345.
3. Walden DT, Marcon NE. Endoscopic injection and polypectomy for bleeding Brunner's gland hamartoma: case report and expanded literature review. *Gastrointest Endosc* 1998;**47**:403-7. doi: 10.1016/s0016-5107(98)70228-7.
  4. Ellis H. The diagnosis of benign and malignant pyloric obstruction. *Clin oncol* 1976;**2**:11-5.
  5. Johnson C, Ellis H. Gastric outlet obstruction now predicts malignancy. *Br J Surg* 1990;**77**:1023-4. doi: 10.1002/bjs.1800770923.
  6. Rana SS, Bhasin DK, Chandail VS, Gupta R, Nada R, Kang M, et al. Endoscopic balloon dilatation without fluoroscopy for treating gastric outlet obstruction because of benign etiologies. *Surg endosc* 2011;**25**:1579-84. doi: 10.1007/s00464-010-1442-y.
  7. Shone DN, Nikoومانesh P, Smith-Meek MM, Bender JS. Malignancy is the most common cause of gastric outlet obstruction in the era of H2 blockers. *Am J Gastroenterol* 1995;**90**:1769-70.