

# Ectopic Location of the Ampulla of Vater Within The Pyloric Channel

S Nasser-Moghaddam<sup>1\*</sup>, H Nokhbeh-Zaeem<sup>1</sup>, Z Soroush<sup>2</sup>,  
S Bani-Solaiman Sheybani<sup>2</sup>, M Mazloum<sup>1</sup>

1. Sharaiti Hospital, Tehran University of Medical Sciences, Tehran, Iran.
2. Mehr General Hospital, Tehran, Iran

## ABSTRACT

The ampulla of Vater is commonly located in the posteromedial wall of the second portion of the duodenum. At times, the ampulla of Vater may be found at uncommon sites such as the third and fourth portions of the duodenum, the duodenal bulb and the stomach. We found the ampulla of Vater in the pyloric channel in a 44 year old patient who had undergone surgery for acute cholecystitis. An intra-operative T-tube cholangiography revealed distal narrowing. The major papilla was not found during endoscopic retrograde cholangiopancreatography (ERCP) and a more accurate T-tube cholangiography revealed that the common bile duct opened in the distal stomach, probably in the pylorus. Finally the ampulla opening was located in the pylorus by methylene blue injection through the T-tube at endoscopy. This rather unusual location of the ampulla of Vater has implications for gastroenterologists performing ERCP.

## KEYWORDS

ERCP; Ampulla of Vater; Ectopic ampulla of Vater; Pyloric channel

## INTRODUCTION

The ampulla of Vater is located in the posteromedial wall of the second portion of the duodenum. The common bile duct (CBD) normally goes through an oblique, 1-2 cm long intramural region beside the medial wall of the second portion of the duodenum and opens into the duodenum.<sup>1-3</sup>

At times, the ampulla of Vater may be ectopic and located in uncommon sites such as the third and fourth portions of the duodenum, the duodenal bulb and the stomach. It has hardly ever been found

at the pylorus.<sup>3-5</sup> This ectopic ampulla goes undetected unless it causes symptoms, usually related to biliary obstruction or cholangitis or when, for some reason, endoscopic retrograde cholangiopancreatography (ERCP) is attempted. Herein we describe a case with ectopic location of ampulla of Vater in the pylorus and review the related literature.

## CASE REPORT

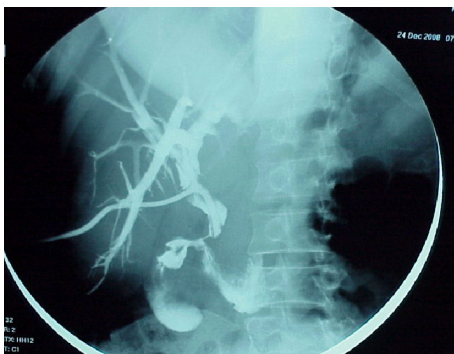
A 44 year old lady with right upper quadrant abdominal pain, high temperature, nausea and vomiting was admitted in

### \*Corresponding Author:

Siavosh Nasser-Moghaddam MD, MPH  
Associate Professor, Digestive Disease  
Research Center, Sharaiti Hospital,  
Tehran University of Medical Sciences,  
Tehran 14117, Iran  
Tel: +98 21 88220022  
Fax: +98 21 82415400  
e-mail: sianasser@yahoo.com  
Received: 13 Oct. 2010  
Accepted: 15 Jan. 2011

the hospital with impression of acute cholangitis. Her laboratory data were as follows: leukocyte count 23,000/mm<sup>3</sup>, total bilirubin 4.6mg/dL, alanine-aminotransferase 80 IU/l (normal <40 IU/ml), aspartate-aminotransferase 153 IU/l (normal <40 IU/ml) and alkaline phosphatase 1,363 IU/l (Normal <290 IU/ml). Transabdominal ultra-sonography showed dilatation of the intra- and extrahepatic bile ducts and gallbladder, and abundant echogenic sludge within the gallbladder. The gallbladder seemed to be partitioned and had two parts. The patient underwent open cholecystectomy, bile duct exploration and extraction of biliary stones. Bougies could not be passed into the duodenum.

A T-tube was inserted and an intra-operative T-tube cholangiography revealed distal narrowing. ERCP was attempted during which no major papilla could be found in the duodenum. A more accurate T-tube cholangiography was performed which revealed that the common bile duct opens in the distal stomach, probably at the pylorus (Figure 1). Endoscopy was done and methylene blue was injected via the T-tube which promptly appeared in the pyloric channel. Considering that there was no filling defect at the T-tube cholangiography and that the site of bile duct opening was not visible without the aid of methylene blue, no further attempt at ERCP was made. The patient had an uneventful recovery and the T-tube was later removed. She is doing well two years after the initial operation without any further bouts of cholangitis.



**Fig. 1:** T-tube cholangiography.

## DISCUSSION

The normal biliary tract originates from the diverticulum hepaticum. Pars hepatica of this embryonic diverticulum gives rise to the intrahepatic and common hepatic ducts. Disruption of the diverticulum hepaticum may lead to anomalies of the biliary tree. When it subdivides very early, the pars hepatica takes a horizontal position above the growth zone between the stomach and duodenum, therefore, it will grow into a duct opening within the stomach.<sup>5</sup> The exact frequency of ectopic biliary drainage is not known, but Saritas et al have reported it to be around 2%.<sup>4</sup> The most common location of ectopic biliary drainage into the stomach is the body of the stomach followed by the antrum and cardia.<sup>4</sup>

To the best of our knowledge, there are only two other cases in the literature that have reported an ectopic opening of the ampulla of Vater within the pyloric channel. Filippini in 1931 described a patient who had jaundice without stones; in this case the common bile duct entered into the pylorus.<sup>6</sup> Another case described by Guerra et al. in 2009 was a 73 year old gentleman with a history of duodenal ulcer who developed cholangitis and choledocholithiasis, and was found to have the ampulla of Vater opening in the pyloric channel.<sup>3</sup> They dilated the ampulla and removed the common bile duct stone using a Dormia basket.

Various methods have been used to detect the ectopic ampulla, including percutaneous transhepatic cholangiography, upper GI endoscopy, ERCP, magnetic resonance cholangiopancreatography and Barium meal.<sup>4,7,8</sup>

In two studies of 18 and 8 patients with ectopic biliary insertions, computerized tomography could not show any specific findings.<sup>9,10</sup>

In our case, T-tube cholangiography was suggestive of an ectopic ampulla and methylene blue injection via the T-tube during endoscopy verified the exact location of the biliary opening. Although this anomaly usually causes no symptoms,

however it may be associated with epigastric pain, dyspepsia and recurrent bouts of fever and jaundice due to cholangitis.<sup>5</sup> The excessive exposure of gastric mucosa to bile may lead to atrophic gastritis, a predisposing condition for gastric adenocarcinoma.<sup>5</sup> In this case the ectopic ampulla of Vater was associated with acute cholecystitis and bile duct stones.

Treatment of ectopic biliary drainage is directed by biliary symptomatology and associated peptic ulcer complications. Current cholangitis needs to be treated and attention paid to protect the patient from recurrent bouts of cholangitis.<sup>4</sup>

Hereby we have reported a rare case of ectopic ampullary insertion within the pyloric channel. This has implications for gastroenterologists performing therapeutic ERCPs who should be aware of the possibility of such anomalies in their practice.

### CONFLICT OF INTEREST

The authors declare no conflict of interest related to this work.

### REFERENCES

1. Sung HY, Kim JI, Park YB, Cheung DY, Cho SH, Park SH, et al. The papilla of Vater just below the pylorus presenting as recurrent duodenal ulcer bleeding. *Intern Med* 2007;**46**:1853-6.
2. Disibeyaz S, Parlak E, Cicek B, Cengiz C, Kuran SO, Oguz D, et al. Anomalous opening of the common bile duct into the duodenal bulb: endoscopic treatment. *BMC Gastroenterol* 2007;**7**:26.
3. Guerra I, Rábago LR, Bermejo F, Quintanilla E, García-Garzón S. Ectopic papilla of Vater in the pylorus. *World J Gastroenterol* 2009;**15**:5221-3.
4. Saritas U, Senol A, Ustundag Y. The clinical presentations of ectopic biliary drainage into duodenal bulb and stomach with a thorough review of the current literature. *BMC Gastroenterol* 2010;**10**:2.
5. Bernard P, Le Borgne J, Dupas B, Kohnen-Shari N, Raoult S, Hamel A. Double common bile duct with ectopic drainage into the stomach. Case report and review of the literature. *Surg Radiol Anat* 2001;**23**:269-72.
6. Quintana EV, Labat R. Ectopic drainage of the common bile duct. *Ann Surg* 1974;**180**:119-23.
7. Scheida N, Wales PW, Krishnamurthy G, Chait PG, Amaral JG. Ectopic drainage of the common bile duct into the lesser curvature of the gastric antrum in a newborn with pyloric atresia, annular pancreas and congenital short bowel syndrome. *Pediatr Radiol* 2009;**39**:66-9.
8. Taourel P, Bret PM, Reinhold C, Barkun AN, Atri M. Anatomic variants of the biliary tree: diagnosis with MR cholangiopancreatography. *Radiology* 1996;**199**:521-7.
9. Lee SS, Kim MH, Lee SK, Kim KP, Kim HJ, Bae JS, et al. Ectopic opening of the common bile duct in the duodenal bulb: clinical implications. *Gastrointest Endosc* 2003;**57**:679-82.
10. Lee HJ, Ha HK, Kim MH, Jeong YK, Kim PN, Lee MG, et al. ERCP and CT findings of ectopic drainage of the common bile duct into the duodenal bulb. *AJR Am J Roentgenol* 1997;**169**:517-20.