



CrossMark

CT Quadrate Lobe Hot Spot Sign

Binit Sureka^{1*}, Aditi Sullere², Pushpinder Singh Khara³

1. Assistant Professor, Department of Diagnostic & Interventional Radiology, AIIMS, Jodhpur, India
2. Senior Resident, Department of Diagnostic & Interventional Radiology, AIIMS, Jodhpur, India
3. Additional Professor & Head, Department of Diagnostic & Interventional Radiology, AIIMS, Jodhpur, India

Please cite this paper as:

Sureka B, Sullere A, Singh Khara P. CT Quadrate Lobe Hot Spot Sign. *Middle East J Dig Dis* 2018;**10**:192-193. doi: 10.15171/mejdd.2018.110.

A 14-year-old girl visited our hospital with pyrexia of unknown origin. In view of suspicion of tuberculosis, various haematological and radiological investigations were done. Further examinations revealed titres positive for lupus anticoagulant syndrome. Contrast-enhanced computed tomography (CT) of the chest and abdomen was also advised for further evaluation, which revealed type II superior vena cava obstruction. Contrast-enhanced CT of the abdomen revealed an interesting observation in the left lobe of the liver, which is known as the hot spot sign.

‘CT quadrate lobe hot spot sign’ was first described by Ishikawa in 1983. It manifests as an area of intense focal wedge-shaped enhancement of the quadrate lobe (functionally a part of the left lobe of the liver and designated segment IVb in the Bismuth-Couinaud classification system) of the liver in the arterial and venous phase (figure 1).¹ This hot spot sign was initially observed on ^{99m}Tc sulphur colloid scan of the liver as a focal area of increased radiopharmaceutical uptake and was diagnostic of superior vena cava syndrome.² Hot spot sign is caused by portosystemic venous shunting between the superior vena cava and the left portal vein via the internal mammary and paraumbilical veins along the ligamentum teres, secondary to superior vena cava obstruction.

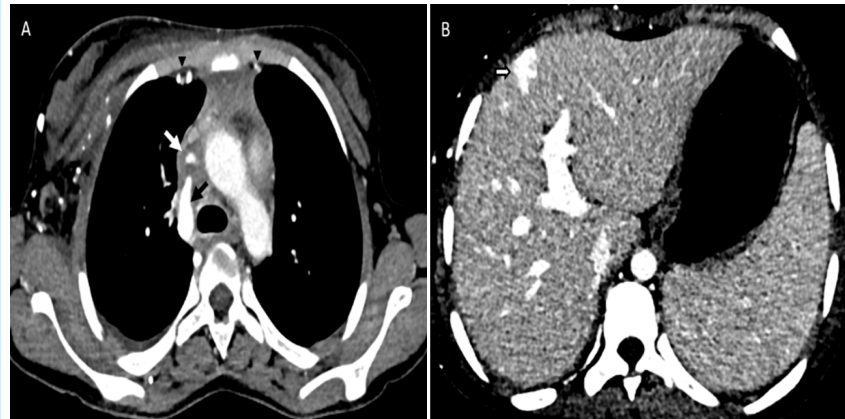


Fig 1: (A) Axial contrast-enhanced tomogram of thorax showing filling defect in SVC (white arrow) suggestive of partial SVC obstruction with the reflux of contrast into the azygous vein (black arrow) and prominent internal mammary veins (arrow heads) and chest wall collaterals (B) Axial tomogram of the liver showing the hot spot sign (arrow) as peripheral wedge shaped abnormal increased enhancement in segment IV.

* **Corresponding Author:**

Binit Sureka, MD
Department of Diagnostic & Interventional Radiology, AIIMS, Jodhpur, India-342005
Telefax: + 91 9013082292
Email: binitSUREKAGPI@gmail.com

Received: 10 Apr. 2018
Accepted: 19 Jun. 2018



© 2018 The Author(s). This work is published by Middle East Journal of Digestive Diseases as an open access article distributed under the terms of the Creative Commons Attribution License (<https://creativecommons.org/licenses/by-nc/4.0/>). Non-commercial uses of the work are permitted, provided the original work is properly cited.

Stanford and colleagues classified SVC syndrome into four types - type I and type II referred as supra-azygous partial and near complete obstruction of SVC with antegrade flow in azygous vein. Type III is defined as complete obstruction of SVC with reversal of azygous blood flow and type IV as complete obstruction of SVC and azygous system with development of chest wall collaterals.³ Two major collateral pathways are visualized on CT in SVC syndrome. One collateral pathway is the SVC–superficial epigastric vein–umbilical vein–left portal vein route. Another collateral pathway is the SVC–internal mammary vein–inferior phrenic vein–subcapsular vein–portal vein route.^{3,4}

The importance of this sign is that it provides a clue to the diagnosis of thoracic SVC obstruction when enhanced CT of the abdomen is performed in clinically unapparent obstruction. The characteristic location in the quadrate lobe of the liver, and wedge shape enhancement in arterial and venous phase are useful in differentiating quadrate hot spot from focal hypervascular liver lesion.

Declaration of patient consent

The authors certify that they have obtained all appropriate patient consent forms. In the form, the patient(s) has/have given his/her/their consent for his/her/their images and other clinical information to be reported in the journal. The patients understand that their names and initials will not be published and due efforts will be made to conceal their identity, but anonymity cannot be guaranteed.

ETHICAL APPROVAL

There is nothing to be declared.

CONFLICT OF INTEREST

The authors declare no conflict of interest related to this work.

REFERENCES

1. Ishikawa T, Clark RA, Tokuda M, Ashida H. Focal contrast enhancement on hepatic CT in superior vena caval and brachiocephalic vein obstruction. *AJR Am J Roentgenol* 1983;**140**:337-8. doi:10.2214/ajr.140.2.337.
2. Dickson AM. The focal hepatic hot spot sign. *Radiology* 2005;**37**:647-8. doi:10.1148/radiol.2372031690.
3. Stanford W, Jolles H, Ell S, Chiu LC. Superior vena cava

obstruction: a venographic classification. *AJR Am J Roentgenol* 1987;**148**:259-62. doi:10.2214/ajr.148.2.259.

4. Baba Y, Miyazono N, Inoue H, Kanetsuki I, Niwatsukino H, Tanaka D, et al. Altered flow dynamics of intravascular contrast material to the liver in superior vena cava syndrome: CT findings. *Abdom Imaging* 2000;**25**:146-50.