



A Rare Cause of Hemoperitoneum in a Patient with Cirrhosis and Portal Hypertension

Cyriac Abby Philips^{1*}, Lijesh Kumar², Mathew Philip³, Prasanth Menon³, Philip Augustine³

1. Department of Hepatology and Transplant Medicine, PVS Institute of Digestive Diseases, PVS Memorial Hospital, Kochi, India
2. Department of Diagnostic and Interventional Radiology, PVS Memorial Hospital, Kochi, India
3. Department of Gastroenterology, PVS Institute of Digestive Diseases, PVS Memorial Hospital, Kochi, India

Please cite this paper as:

Philips CA, Kumar L, Philip M, Menon P, Augustine P. A Rare Cause of Hemoperitoneum in a Patient with Cirrhosis and Portal Hypertension. *Middle East J Dig Dis* 2017;9:118-119. DOI: 10.15171/mejdd.2017.62.

A 48-year-old man, diagnosed case of portal hypertension secondary to alcohol related cirrhosis of the liver, presented to the gastrointestinal (GI) Bleed Unit, with jaundice and worsening abdominal distension for a period of five days. Clinical examination revealed an emaciated patient in grade 2 hepatic encephalopathy with pulse rate 98 per minute and mean arterial pressure 66 mmHg in the right supine brachial region, with Child Pugh score 10 and Model for End Stage Liver Disease score 18. Upper GI endoscopic evaluation revealed small low risk esophageal varices without active bleeding or stigmata of recent hemorrhage and normal colonoscopy. Bedside diagnostic paracentesis revealed bloody aspirate with fluid hematocrit 17% and fluid red blood cell count of 35,000 per mm³ suggestive of hemoperitoneum. An urgent computed tomography (CT) angiography of the abdomen revealed shrunken dysmorphic liver with hyper dense free fluid and dependent clots in pelvis without active bleeding. Interestingly, multiple thread-like structures with contrast opacification in venous phase were noted in the distal duodenum and jejunal region [black arrows (Figure 1A, maximal intensity projection, CT coronal) and corresponding white arrows (Figure 1B, CT curved planar reformation, 3-dimensional)] along with multiple contrast opacified mesenteric and retroperitoneal vessels (Figure 1C, asterisk). Commencement of broad spectrum antimicrobials, blood transfusions, and terlipressin with serial hemoglobin monitoring, and abdominal girth charting was undertaken. The patient had an uneventful recovery from the bleeding episode and is currently listed in the deceased donor liver transplantation program.

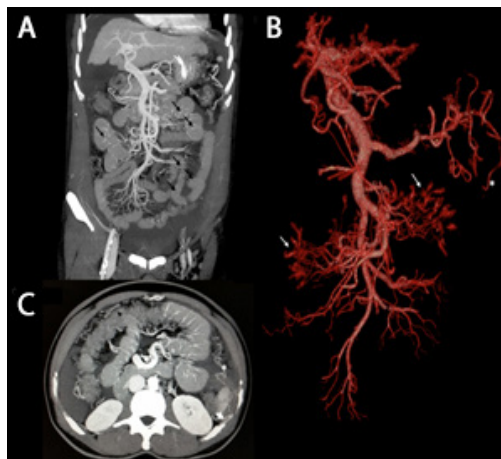


Fig. A,B,C: CT angiography of the abdomen showing shrunken dysmorphic liver with hyper dense free fluid and dependent clots in pelvis without active bleeding with distal duodenal and jejunal varices [black arrows (A, maximal intensity projection, CT coronal) and corresponding white arrows (B, CT curved planar reformation, 3-dimensional)] with associated multiple mesenteric (C, asterisk) and retroperitoneal ectopic varices with surrounding hematoma (C, white arrow head).

*** Corresponding Author:**

Cyriac Abby Philips, MD
Philip Augustine Associates,
PVS Memorial Hospital Campus, Kaloor,
Kochi, Kerala, India
Telefax: + 91 0484 418 2888
Email: abbyphilips@gmail.com

Received: 21 Dec. 2016

Accepted: 10 Mar. 2017

What is your diagnosis?

Answer:

The CT findings are classical of bleeding from mesenterico-retroperitoneal ectopic varices in the presence of surrounding ‘sentinel clot’ (figure 1C, white arrow head). The patient also has multiple small intestinal ectopic varices, which are unlikely to be the source of bleeding. The latter usually presents with hypotension and melena or bleeding per rectum. Ectopic varices are dilated portosystemic collateral veins located in unusual sites other than the gastroesophageal region accounting for up to 5% of variceal bleedings and present with hematemesis or hematochezia, hemoperitoneum or obscure GI bleeding.¹⁻³ Small bowel varices occur rarely with localized cause of portal hypertension and are more frequent in cirrhosis. Afferents to small bowel ectopic varices are jejuno-ileal veins (tributaries of superior mesenteric vein) and the efferents generally drain into abdominal wall or into veins of Retzius.³ Spontaneous rupture of ectopic varices is very rare, but catastrophic with only close to 40 cases reported in the literature with umbilical, peri-umbilical, omental, retroperitoneal, round ligament-related, and mesenteric varices.^{2, 3} Presentation is with hypovolemic shock with mortality reaching up to 70%. Saad and Caldwell classified ectopic varices into two broad etiologies; global portal hypertension (oncotic or non-occlusive type), and splanchnic (mesocaval) venous occlusion (occlusive type), which helps in deciding therapy.² There are no set guidelines for the management of bleeding ectopic varices. The location of variceal bleed, clinical presentation, and the underlying medical disease dictate treatment decisions, which can include double balloon enteroscopy and transcatheter embolization or sclerotherapy, with or without portosystemic decompression. Transjugular intrahepatic portosystemic shunt (TIPSS), balloon occluded retrograde transvenous obliteration, and percutaneous trans-hepatic obliteration with coil embolization of the veins draining into the ectopic varices are other advanced interventional options.^{3,4} Our patient had a fortunate self-limiting bleed without re-bleed episodes in hospital, a matter of rarity.

CONFLICT OF INTEREST

The authors declare no conflict of interest related to this work.

REFERENCES

1. Watson GA, Abu-Shanab A, O’Donohoe RL, Iqbal M. Enteroscopic Management of Ectopic Varices in a Patient with Liver Cirrhosis and Portal Hypertension. *Case Reports Hepatol* 2016; **2016**:2018642. doi:

10.1155/2016/2018642.

2. Saad WE, Lippert A, Saad NE, Caldwell S. Ectopic varices: anatomical classification, hemodynamic classification, and hemodynamic-based management. *Tech Vasc Interv Radiol* 2013;**16**:158-75. doi: 10.1053/j.tvir.2013.02.004.
3. Sarin SK, Kumar CKN. Ectopic varices. *Clin Liv Dis* 2012;**1**:167-72.
4. Abutaka A, Koshy RM, Abu Sabeib A, Toro A, Di Carlo I. Spontaneous hemoperitoneum, due to bleeding from retroperitoneal varices, in a cirrhotic patient: a case report. *Clin Case Rep* 2015;**4**:51-3. doi: 10.1002/ccr3.427. eCollection 2016.