

Clinical, Endoscopic, and Histopathological Aspects of Sigmoid Actinomycosis; A Case Report and Literature Review

Farhad Zamani^{1*}, Masoudreza Sohrabi¹

1. Gastrointestinal and Liver Disease Research Centre (GILDRC), Iran University of Medical Sciences, Tehran, Iran

ABSTRACT

Actinomycosis is a rare and chronic infectious disease caused by a non-spore gram-positive, anaerobic bacterium that rarely infects the colon, in particular the left colon.

A 53-year-old woman was referred to us due to chronic abdominal pain, bloating, a few episodes of bloody-mucous rectal discharge, and change of bowel habits. Her medical history and physical examination were unremarkable. Colonoscopy revealed a polypoid mass like lesion located 20 cm proximal to the anal verge above the rectosigmoid junction. Several biopsy samples were taken. Histopathological evaluation showed actinomycosis infection. Consequently the patient was treated with intravenous and then six months oral penicillin. Her complaints and colonic mass resolved totally.

Diagnosis of colonic actinomycosis is not an easy task. It is advisable to keep this infection in mind among the differential diagnoses of unusual abdominal masses. Colonoscopy and histopathological examination can be the preferred modality for diagnosis of colonic actinomycosis infection.

KEYWORDS

Actinomycosis; Left colon; Sigmoid; Penicillin

Please cite this paper as:

Zamani F, Sohrabi MR. Clinical, Endoscopic, and Histopathological Aspects of Sigmoid Actinomycosis; a Case Report and Literature Review. *Middle East J Dig Dis* 2015;7:41-4.

INTRODUCTION

Actinomycosis is a rare chronic, granulomatous, suppurative, and progressive infectious disease, which is characterized by the development of sinuses that may secrete sulfur granules.¹⁻² The common cause of this infection in humans is *Actinomyces israelii*.³ This is a non-spore gram-positive, anaerobic bacterium that is universally distributed. This bacterium is not very virulent and frequently arises from cervicofacial mucosa (50%), abdominal (20%), and thoracic (15%) areas that cause opportunistic infections. Patients with immunosuppressive state such as recipients of chemotherapy or organ transplant are at risk of opportunistic infections and morbidity and mortality.^{1,4} Nevertheless, primary bowel involvement has not been reported frequently. In this context the transverse colon and cecum are the most common sites of manifestation.

The diagnosis of actinomycosis infection due to its unspecific clinical picture is not easy. Based on previous reports, abdominal actinomycosis can imitate the presentation of other abdominal pathologies such as

* Corresponding Author:

Farhad Zamani, MD
Gastrointestinal and Liver Disease Research Center (GILDRC), Iran University of Medical Sciences, Tehran, Iran
Telefax: +98 21 88941831
Email: zamani.farhad@gmail.com
Received: 28 Jul. 2014
Accepted: 18 Nov. 2014

malignancy, abscesses, inflammatory bowel disease (IBD), and diverticulitis.^{3,4} Therefore, the diagnosis of infection could be a challenging process. This bacterium is usually detected by histopathological examination.

Herein we report a case of primary sigmoid colon actinomycosis in an otherwise healthy 53-year-old lady. We also complete the report with review of the related literature.

CASE REPORT

A 53-year-old woman presented with 6 months history of generalized vague abdominal pain, bloating, and a few episodes of bloody-mucous rectal discharge with change of bowel habit. Her medical and drug history were unremarkable. She had never used intrauterine devices and reached menopause at the age of 48 years.

The patient was afebrile and her vital signs were stable. Physical examination was unremarkable except for mild generalized abdominal tenderness without rebound or involuntary guarding. The laboratory examinations revealed a mild normocytic anemia (hemoglobin=11.7 gr/dL with MCV=82 fl), C-reactive protein (CRP) was in the normal range, and erythrocyte sedimentation rate (ESR) was 13 mm/hr. Abdominal and pelvic ultrasonographic studies were also normal.

Colonoscopy showed a polypoid mass like lesion in the distal part of the sigmoid colon with some amount of necrotic material around the lesion (figures 1, 2). It was located 20 cm proximal to the anal verge, above the rectosigmoid junction. Several biopsy samples were taken for histopathological study. Microscopic examination of the specimen revealed ulcerated and slightly inflamed large intestinal mucosa with polypoid inflammatory granulation tissue, and a small amount of fibrin purulent exudates, sometimes enclosing bacterial colonies in forms of branching filaments morphologically compatible with actinomyces (figures 3, 4).

After confirming the diagnosis, intravenous penicillin (20 million IU/day) was prescribed. The patient received intravenous treatment for 10 days and continued with oral penicillin V (2 gr/day) for next six months.

She was discharged after ten days and her complaints and colonic mass resolved totally (figures 5,6).

DISCUSSION

The first paper ever reported on abdominal actinomycosis was published more than 80 years ago.¹ This organism is considered as a normal flora of the digestive, respiratory, and female genital systems. As a result any processes that makes a breach in the normal mucosa such as surgery or trauma can be a trigger for pathologic proliferation of actinomycosis,^{3,5} although the pathophysiology of this phenomenon is not fully known. Usual predisposing factors include immune suppression, surgery, diverticulitis, foreign body, and bowel perforation. However in many of patients no predisposing factor was reported.⁴

Abdominal actinomycosis is not a common clinical issue having a non-specific clinical presentation. It always presents as a slow growing mass that alters the bowel habits, and is accompanied by abdominal pain and cramps, and constitutional symptoms. Abdominal mass detected either clinically or radiologically is a usual finding that mimics other abdominal pathologies. Radiological evaluations are usually non-specific. Digestive actinomycosis seldom presents as an abdominal abscess with or without a discharging sinus into the abdominal or perianal sites. It can also occasionally present as an acute abdomen. The most frequently encountered laboratory findings are anemia, leukocytosis, and positive inflammatory markers. Although the involvement of the left side of the colon is rare, right side of the colon and the ileocecal involvement is also common.^{1,4,6}

The efficacy of colonoscopy for the diagnosis of extramucosally originating actinomycosis is low but it is usually used to exclude inflammatory or neoplastic conditions. However, in the presence of a mass in intestinal lumen, histological evaluation of endoscopically removed specimen can confirm the diagnosis. Computed tomography (CT scan) is an applicable modality for detection of a mass and to explore the adjacent area but for actinomycosis it is not diagnostic.⁷ Nevertheless, CT-guided drainage of an abscess can give an appropriate sample for iden-

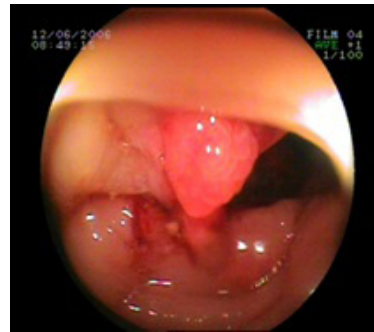
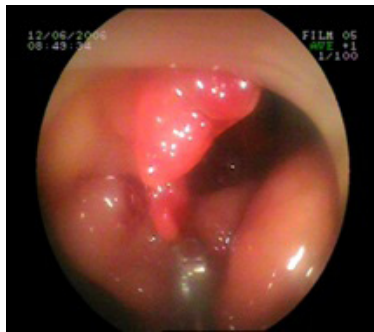
Fig. 1&2: The polypoid mass like lesion in the distal part of the sigmoid colon

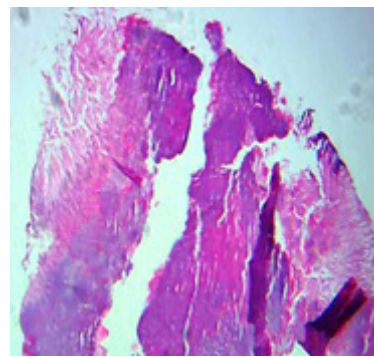
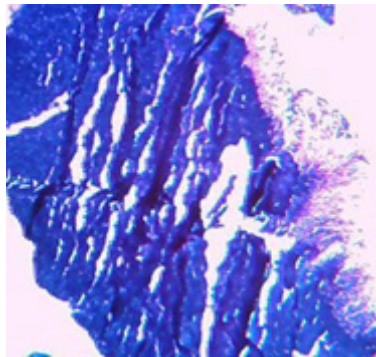


Fig. 3&4: The histopathological features of the lesion

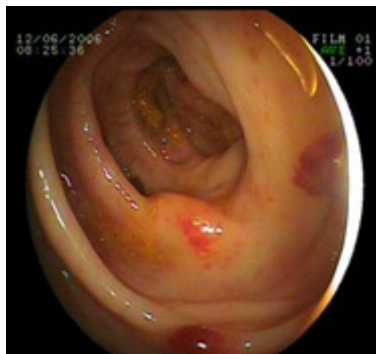

Fig. 5: The lesion was resolved after treatment

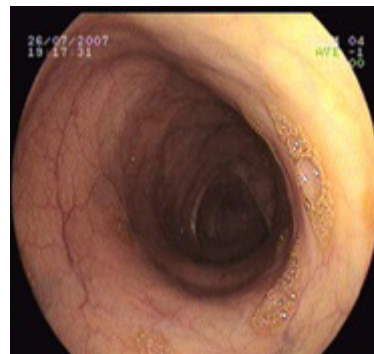


Fig. 6: The colon one year after treatment

tification of the organism. In most of the cases the radiological findings resemble an IBD presentation. Usually the findings include mural invasion along with stricture formation or presence of a mass in the lumen with thickenings of the mucosa.^{1,7-8} Most of actinomyces infections are diagnosed histopathologically. Microscopic examination of the removed specimen may show the frequently described “sulfur granules”. In fact, sulfur granules have been detected in about 50% of cases.²⁻³ It should be mentioned that sulfur granules can be observed in other infections

caused by *Nocardia* and some types of staphylococci. Definitive diagnosis rests on the specimen culture or the use of specimen-specific antibodies but this is not easy to perform in the clinical setting.⁸

In our presented case, actinomyces had affected an area 20 cm above the anal verge, which is a very rare incident. Also, the patients did not indicate any predisposing factors. In addition, the clinical and laboratory findings only revealed mild lower gastrointestinal symptoms with normocytic anemia. All of them make this case almost unique

compared with previous reports. While in previous reports the abdominal actinomycosis usually tends to express itself in a more prominent clinical picture and elevated serum levels of inflammatory markers that resemble other abdominal pathologies such as malignancy, IBD, or tuberculosis.^{3,8}

If the diagnosis can be confirmed without surgery and the patient does not experience complications, non-surgical treatment with a high dose penicillin is the first choice.

In conclusion, colonic actinomycosis should be kept in mind as a rare differential diagnosis of abdominal mass, with either tumoral or inflammatory characteristics. Colonoscopy and histopathological study of the removed specimen can be considered as the first choice modality for the diagnosis of colonic actinomycosis. High index of suspicion leads to an immediate and accurate diagnosis by clinicians and can prevent unnecessary surgical intervention.

CONFLICT OF INTEREST

The authors declare no conflict of interest related to this work.

REFERENCES

1. Triantopoulou C, der Molen AV, Es AC, Giannila M. Abdominopelvic actinomycosis: spectrum of imaging findings and common mimickers. *Acta Radiol Short Rep* 2014;**3**:2047981614524570.
2. Bennhoff DF. Actinomycosis: diagnostic and therapeutic considerations and a review of 32 cases. *Laryngoscope* 1984;**94**:1198-217.
3. Wong VK, Turmezei TD, Weston VC. Actinomycosis. *BMJ* 2011;**343**:d6099.
4. Naf F, Enzler-Tschudy A, Kuster SP, Uhlig I, Steffen T. Abdominal Actinomycosis Mimicking a Malignant Neoplasm. *Surg Infect (Larchmt)* 2014;**15**:462-3.
5. Petrie BA, Schwartz SI, Saltmarsh GF. Intra-abdominal Actinomycosis in Association with Sigmoid Diverticulitis. *Am Surg* 2014;**80**:157-9.
6. Majernik J, Bis D, Hanousek P, Ninger V. [Abdominal actinomycosis - 3 case reports and literature overview]. *Rozhl Chir* 2013;**92**:260-3.
7. Bae JH, Song R, Lee A, Park JS, Kim MR. Computed tomography for the preoperative diagnosis of pelvic actinomycosis. *J Obstet Gynaecol Res* 2011;**37**:300-4.
8. Privitera A, Milkhu CS, Datta V, Rodriguez-Justo M, Windsor A, Cohen CR. Actinomycosis of the sigmoid colon: A case report. *World J Gastrointest Surg* 2009;**1**:62-4.