

## Simultaneous Esophageal Squamous Cell Carcinoma and Adenocarcinoma: A Case Report

Iradj Maleki<sup>1</sup>, Ramin Shekarriz<sup>2\*</sup>, Anahita Nosrati<sup>3</sup>, Elahe Orang<sup>4</sup>

1. Associate Professor, Department of Gastroenterology, Inflammatory Diseases of Upper Gastrointestinal Tract Research Center, Mazandaran University of Medical Sciences, Sari, Iran
2. Assistant Professor, Department of Adult Hematology and Oncology, Department of hematology and oncology, Mazandaran University of Medical Sciences, Sari, Iran
3. Assistant Professor, Department of Pathology, Mazandaran University of Medical Sciences, Sari, Iran
4. Research Assistant, Inflammatory Diseases of Upper Gastrointestinal Tract Research Center, Mazandaran University of Medical Sciences, Sari, Iran

**\* Corresponding Author:**

Ramin Shekarriz, MD  
Hematology & Oncology department, Imam Khomeini Hospital, Razi St., Sari, Iran  
Tel: +98 11 33371700  
Fax: +98 11 33374977  
Email: raminshf@gmail.com  
Received: 11 Jun. 2015  
Accepted: 01 Sep. 2015

### ABSTRACT

Esophageal squamous cell carcinoma is a rather common cancer in northern Iran. Incidence of adenocarcinoma of esophagus has an increasing trend in Iran. Co-existence of both cancers in one patient is very rare. We report a middle age woman from northern Iran with a typical presentation of esophageal cancer, who was found to have a dual esophageal cancer. The disease was found in the advanced stage with pulmonary metastasis at the presentation. Palliative chemo-radiotherapy induced partial clinical response.

### KEYWORDS

Esophageal Neoplasms; Squamous Cell Carcinoma; Adenocarcinoma; Second Primary Neoplasm

Please cite this paper as:

Maleki I, Shekarriz R, Nosrati A, Orang E. Simultaneous Esophageal Squamous Cell Carcinoma and Adenocarcinoma: *Middle East J Dig Dis* 2015;7:258-61.

### INTRODUCTION

Esophageal cancer (EC) is a considerable health challenge in northern Iran<sup>1</sup>, which is located on “esophageal cancer belt” recognized as the highest risk area for the disease.<sup>2</sup> Pathologically, EC can be classified into two major types called esophageal squamous cell carcinoma (ESCC) and adenocarcinoma. ESCC is the most common type (90%) of esophageal malignancies in Asian countries.<sup>2</sup> Esophageal adenocarcinoma (EAD) is the most common malignant tumor that originates from Barrett’s esophagus. During the past decades, incidence rate for EAD has been rising in some western countries because of increases in the prevalence of risk factors such as gastroesophageal reflux disease (GERD), obesity, and overweight.<sup>3-7</sup> A recent study showed a considerable increasing trend in EAD incidence rate in a high ESCC risk area in northeast of Iran.<sup>8</sup>

Recently, other more uncommon types of EC and collision tumors with various histological categories of tumors have been reported.<sup>9-15</sup> By definition, a collision tumor is the concrescence of two neighboring independent tumors expanding into each other.<sup>9-16</sup> which often occurs in the gastroesophageal junction. Collision tumors have not been well-recognized yet, but each tumor may need different treatment and usually has unfavorable prognosis. Separate primary carcinomas or non-collision dual primary carcinomas occurring simultaneously in the esophagus are quite very uncommon. In this report, we describe a patient with simultaneous ESCC and EAD.

## CASE REPORT

A 58-year-old Iranian woman was visited in our gastroenterology clinic, Sari, Iran in October 2012. She complained of progressive dysphagia to solid food for about four months accompanied by postprandial back radiating and epigastric pain. She did not seek any medical treatment during this period. For the last four months she also experienced loss of appetite and significant weight loss (15 kg). There was no history of smoking, alcohol consumption, and previous surgery. Her medical history showed only prominent symptoms of gastroesophageal reflux disease. The family history was not positive for malignancies. On admission, she was 157 cm tall, weighed 45 kg and was moderately poor nourished (BMI=18 kg/m<sup>2</sup>). Physical examination revealed no abnormalities, except for cachexia, and pallor in conjunctivae. Esophagogastroduodenoscopy (EGD) showed a red irregular round and plate like lesion with raised borders at midesophagus (29-31 cm from dental arc, figure 1). Furthermore another huge mass was seen beginning from the distal esophagus extending to cardia and fundus (figures 2 & 3).

The main bulk of the tumor could be inspected in the retroversion maneuver in fundus. This mass was very fragile and bled either spontaneously and on touch. Separate biopsy samples were taken from both the above described lesions. Accordingly pathological evaluation was performed by two experienced pathologists. Sections from the esophageal lesion displayed a malignant epithelial neoplasm composed of infiltrative nests of pleomorphic squamous cells with focally preserved inter-cellular bridges and a little keratin pearls formation. The cells had atypical oval hyperchromatic to vesicular nuclei with conspicuous nucleoli and modest eosinophilic cytoplasm. Sections from the distal esophageal tumor showed infiltrative irregular medium-sized glands lined by pleomorphic columnar cells. The cells characterized by mildly hyperchromatic enlarged nuclei with eosinophilic cytoplasm. Taking the above histological findings into account, moderately differentiated squamous cell carcinoma and well differentiated adenocarcinoma were diag-

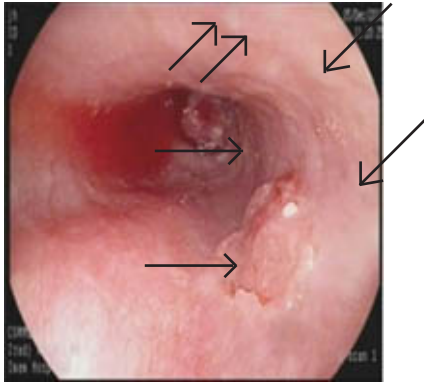
nosed (figures 4 & 5).

Thoraco-abdominal computed tomography showed high density pulmonary nodules in right and left upper lobes along with a large mass with necrotic areas at medial wall of gastric fundus and cardia. Abnormal laboratory findings at the time of admission included iron deficiency anemia and an increased carcino-embryonic antigen (CEA) of 125 ng/ml.

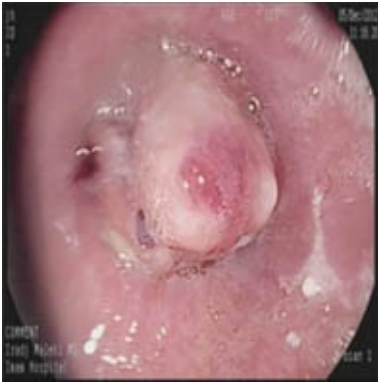Considering the lung metastasis and patient's refusal for any surgical intervention, a palliative chemotherapy was offered to the patient. Palliative chemotherapy with DCF regimen (Docetaxel, Cisplatin, 5FU) was administered and discontinued after 4 cycles due to lack of patient's compliance. Then she was referred to radiotherapy ward and received platinum-based chemo-radiation (5040 cGy in 28 fractions). During this period, she was on a soft diet and her symptoms relieved after each course of chemotherapy. During the treatment course an attack of pneumonia occurred, which was controlled by hospital admission and antibiotics prescription (imipenem and vancomycin). After 6 months the patient's symptoms including pain and dysphagia were aggravated. Seven months later, EGD revealed the tumoral ulcerative lesion which diffusely extended from distal esophagus to cardia/fundus and involved lesser gastric curvature as well. The esophageal SCC did not show any prominent grow. Metastatic pulmonary nodules were unchanged on control computed tomography. Therefore she was followed up with supportive care. In June 2014, the patient is still alive after 19 months of follow-up. However, she is presented again with anorexia, deterioration in dysphagia to both liquids and solids and epigastric pain after food.

## DISCUSSION

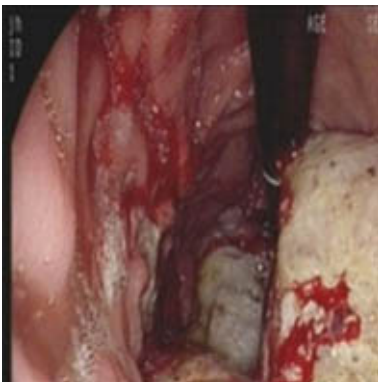
Here we have reported an advanced (stage 4) esophageal cancer, with pathologically confirmed simultaneous ESCC and EAD. The patient lives in a high prevalence area for esophageal SCC 1 and in this condition one could imagine any other disease to be concordant with the primary disease. It stands to reason that simultaneous cancers with dif-



**Fig 1:** Endoscopy showing mid-esophageal squamous cell carcinoma (Thin arrows) and distal esophageal adenocarcinoma (thick arrows)

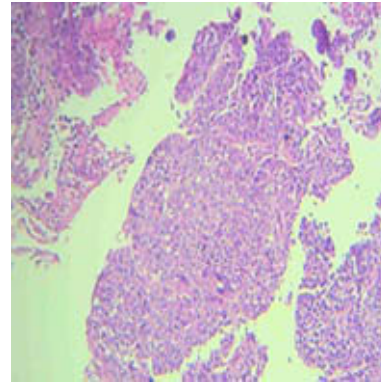


**Fig 2:** Endoscopy showing the distal esophageal adenocarcinoma

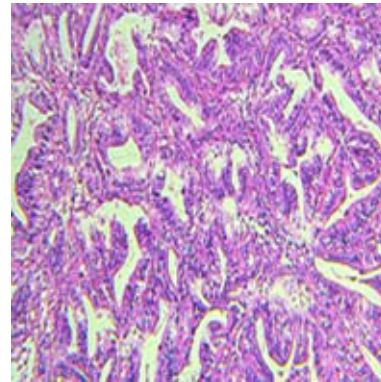


**Fig 3:** Endoscopy showing the cardia and fundal extension of the adenocarcinoma

ferent histology and risk factors in a single patient are interesting enough to be emphasized. Having common risk factors for both conditions could be one theory for the co-occurrence of dual cancers. Tobacco and alcohol consumption have been considered as major common etiologic risk factors for



**Fig 4:** Esophagus, mid part squamous cell carcinoma, moderately differentiated, H & E (10x)



**Fig 5:** Esophagus, distal part, adenocarcinoma, well differentiated, H & E (10x)

EC,7 but our patient's medical history revealed that she was exposed to none of them. However, nutritional and genetic susceptibility for these malignancies cannot be ruled out in this setting.

One concern regarding this case is determining the source of her adenocarcinoma. Is it originated from distal esophagus with downward extension to cardia/ fundus? Or is it originally a cancer of cardia with upward extension into distal esophagus? This distinction is always not easily made for the malignancies of this anatomical area. In fact, in the routine medical practice they are usually grouped and discussed together.

This case of simultaneous cancers of esophagus cannot be regarded as a collision tumor as they were apart from each other. This distinction appears not to be different conceptually, but it is a matter of the site of the primary genesis of tumoral lesions. It is considered that in the setting of a collision tumor,

both tumors develop in different sites. Then, during their course of growth they reach each other and present as back to back tumors with different histology within a single tumoral mass.<sup>9</sup>

An important issue in this case is the separate histological evaluation of the two lesions in the upper GI tract. The endoscopist could think of secondary involvement of the smaller lesion in the mid-esophagus and submucosal metastasis of the larger adenocarcinoma of cardia and ignore the histological evaluation of this lesion. In this case with an advanced metastatic stage, this differentiation may appear not to be much important; however, clinical course, treatment modalities, response to treatment, and overall prognosis of different malignancies could be different. Thus, we do recommend taking biopsy samples and evaluating any lesion pathologically as a single and separate one, to view the complete picture of the disease.

ESCC appears to have a more favorable prognosis with the available non-surgical and surgical interventions compared to EAD. In our case with a short and incomplete palliative chemo-radiotherapy the ESCC had a good response with acceptable regression, but the EAD component showed non-significant changes except some subjective improvements. Finally, a roughly two year survival for this case is interesting having both malignancies at the same time.

We were not able to evaluate the esophageal and cardia tumor with the endoscopic ultrasound because of the lack of availability of the instrument in this city and patient's non-compliance for doing it in a more facilitated center. As the patient had a metastatic disease from the beginning, we did not insist on this procedure for the evaluation of the local extent of her malignancy.

#### CONFLICT OF INTEREST

The authors declares no conflict of interest related to this work.

#### REFERENCES

- Roshandel G, Khoshnia M, Sotoudeh M, Merat S, Etemadi A, Nickmanesh A, et al, Endoscopic screening for precancerous lesions of the esophagus in a high risk area in Northern Iran. *Arch Iran Med* 2014;**17**:246-52.
- Jemal A, Bray F, Center MM, Ferlay J, Ward E, Forman D. Global cancer statistics. *CA Cancer J Clin* 2011;**61**:69-90.
- El-Serag HB. Time trends of gastroesophageal reflux disease: a systematic review. *Clin Gastroenterol Hepatol* 2007;**5**:17-26.
- Post PN, Siersema PD, Van Dekken H. Rising incidence of clinically evident Barrett's oesophagus in The Netherlands: a nation-wide registry of pathology reports. *Scand J Gastroenterol* 2007;**42**:17-22.
- Brown LM, Devesa SS, Chow WH. Incidence of adenocarcinoma of the esophagus among white Americans by sex, stage, and age. *J Natl Cancer Inst* 2008;**100**:1184-7.
- Pera M, Manterola C, Vidal O, Grande L. Epidemiology of esophageal adenocarcinoma. *J Surg Oncol* 2005;**92**:151-9.
- Napier KJ, Scheerer M, Misra S. Esophageal cancer: A Review of epidemiology, pathogenesis, staging workup and treatment modalities. *World J Gastrointest Oncol* 2014;**6**:112-20.
- Ghasemi-Kebria F, Roshandel G, Semnani S, Shakeri R, Khoshnia M, Naeimi-Tabiei M, et al, Marked increase in the incidence rate of esophageal adenocarcinoma in a high-risk area for esophageal cancer. *Arch Iran Med* 2013;**16**:320-3.
- Wang L, Zhan C, Ma J, Shi Y, Wang Q. Collision tumor of esophagus: report of three cases. *Ann Thorac Surg* 2014;**97**:1075-7.
- Naritaka Y, Ogawa K, Shimakawa T, Wagatsuma Y, Isohata N, Asaka S, et al, Collision carcinoma of the residual cervical esophagus 27 years after esophageal cancer surgery. *Anticancer Res* 2007;**27**:505-11.
- Firat O, Yazici P, Makay O, Aydin A, Tuncyurek M, Ersin S, et al, Co-existence of gastrointestinal stromal tumors with malign epithelial tumors: a report of two cases. *Acta Chir Belg* 2009;**109**:629-32.
- Kaidar-Person O, Naroditsky I, Guralnik L, Kremer R, Bar-Sela G. Collision tumor of the mediastinum: a rare entity. *Ann Thorac Surg* 2013;**95**:330-2.
- Wilson CI, Summerall J, Willis I, Lubin J, Inchausti BC. Esophageal collision tumor (Large cell neuroendocrine carcinoma and papillary carcinoma) arising in a Barrett esophagus. *Arch Pathol Lab Med* 2000;**124**:411-5.
- Qian T, Gao F, Chen MZ, Meng FH, Li XJ, Liu YJ, et al., Collision tumor of the esophagus: report of a case with mixed squamous cell carcinoma and gastrointestinal stromal tumor. *Int J Clin Exp Pathol* 2014;**7**:1206-11.
- González LM, Sanz-Esponera J, Saez C, Alvarez T, Sierra E, Sanz-Ortega J. Case report: esophageal collision tumor (oat cell carcinoma and adenocarcinoma) in Barrett's esophagus: immunohistochemical, electron microscopy and LOH analysis. *Histol Histopathol* 2003;**18**:1-5.
- DODGE OG. Gastro-oesophageal carcinoma of mixed histological type. *J Pathol Bacteriol* 1961;**81**:459-71.