

Hepatocellular Carcinoma in Pregnancy with Unusual Presentations

Alireza Norouzi¹, Mohammad Naeimi Tabei², Samaneh Tavassoli³, Sima Besharat^{1*}

1. Golestan Research Center of Gastroenterology and Hepatology, Golestan University of Medical Sciences, Gorgan, Iran.
2. Golestan University of Medical Sciences, Gorgan, Iran.
3. Mazandaran University of Medical Sciences, Sari, Iran.

ABSTRACT

Hepatocellular carcinoma (HCC) is very rare during pregnancy and has a worse prognosis in pregnant women compared to those who are not pregnant. We present a case of HCC in a 41-year-old pregnant patient who was referred to our academic hospital.

The patient presented with chief complaints of abdominal pain, jaundice, edema and hypertension. Laboratory results were notable for elevated liver enzymes and features of microangiopathic hemolytic anemia with normal alpha fetoprotein (AFP) and elevated cancer antigen 125 (CA125). At laparotomy for termination of pregnancy, multiple massive lesions were detected in the liver. Histologic evaluation showed features of HCC.

HCC must be included in the differential diagnosis of any pregnant patient who presents with elevated liver enzymes and hemolysis.

KEYWORDS

Hepatocellular carcinoma (HCC); Pregnancy; Prognosis

Please cite this paper as:

Norouzi A, Naeimi Tabei M, Tavassoli S, Besharat S. Hepatocellular Carcinoma in Pregnancy with Unusual Presentations. *Middle East J Dig Dis* 2012;4:228-31.

INTRODUCTION

Hepatocellular carcinoma (HCC) is an important, rare entity during pregnancy.¹ The age-standardized incidence is approximately 1 per 100,000 women in the United States¹ and few cases have been reported since 1957.²⁻⁴ HCC is aggressive during pregnancy and has a poor prognosis with an overall one-year survival of 23%,⁵ which could be explained by two main etiologies: estrogen elevation which accelerates the evolution of HCC and immune suppression during pregnancy.⁴ It is associated with fetal loss in 42% of cases.³

We present a case of HCC in a 41-year-old pregnant patient who referred to our academic hospital with abdominal pain, icter, laboratory features of microangiopathic hemolytic anemia and low alpha fetoprotein (AFP).

CASE REPORT

A 41-year-old pregnant woman referred to our hospital in the 22nd week of gestational age with right upper abdominal pain and jaundice. She had mild abdominal pain six weeks before presentation which was aggravated one week before admission. Abdominal pain was not relat-

* Corresponding Author:

Sima Besharat, MD
3rd floor, Shahid Nabavi Polyclinic, 4th Azar St., 5th Azar Boulevard, Gorgan, Iran
Tel: + 98 171 2340835
Fax: +98 171 2269210
Email: s_besharat_gp@yahoo.com
Received: 14 May 2012
Accepted: 29 Jul. 2012

ed to food intake and referred to her right shoulder. Four days before admission, she had icter, tea colored urine and edema in her lower extremities. She had nausea and vomiting but no headache, blurred vision or bleeding was mentioned. She mentioned fatigue and hypertension from the eighth week of pregnancy. A past history was remarkable for two abortions and one live birth prior to this pregnancy. She took only ferrous sulfate and aspirin in this pregnancy and no other drugs, herbal medicines or oral contraceptives (OCPs).

There was no history of blood transfusion, hepatitis or exposure to aflatoxin in her past history however her father died from HCC due to hepatitis B virus (HBV). Laboratory investigations showed features of microangiopathic hemolytic anemia that included schistocytes, elevated prothrombin time and erythrocyte sedimentation rate (ESR), and negative viral markers (negative HBsAg and HBcAb). Differential diagnoses of HELLP syndrome, thrombotic thrombocytopenic purpura (TTP) or acute fatty liver of pregnancy (AFLP) were made for further evaluation and management.

She seemed ill and icteric at admission but not toxic. Her blood pressure was 110/70 mmHg with a pulse rate of 110 beats/min, respiratory rate about 18/min and oral temperature of 37°C. Conjunctivae was pale and sclera was icteric. Jugular venous pressure was normal. Pulmonary sounds were diminished in the basal parts but cardiac examination showed no abnormalities. Her abdomen was tender, particularly in the right upper quadrant, but without rebound and guarding. Lower extremities had 3+ pitting edema and there were ecchymotic lesions at previous injection sites.

Laboratory examination showed leukocytosis, anemia and lower limit platelet counts. Blood electrolytes were normal but there was direct hyperbilirubinemia and liver enzymes showed a cholestatic pattern. Lactate dehydrogenase (LDH) was elevated and haptoglobin was low. Peripheral blood smear showed features of microangiopathic hemolytic anemia that included target cells, tear drop and nucleated RBCs, and numerous schistocytes. Urine analysis was positive for microscopic hematuria

and proteinuria. A 24-hour urine collection showed 226 milligrams of protein.

Viral markers of HBV and HCV, autoantibodies and Adisintegrin-like and metalloproteinase with thrombospondin type 1 motif (Adamts)-13 antigen and antibody (markers for Thrombotic Thrombocytopenic purpura=TTP) were all negative. AFP level was 90.7 and cancer antigen 125 (CA125) titer was >1000.

Transabdominalsonography showed a normal fetus with a gestational age of about 23 weeks and normal amniotic fluid in the breech position. The liver showed a coarse echopattern with a diameter of 20 cm. The biliary ducts were normal and the gallbladder was contracted. No lesion was noted in the portal vein, which had a diameter of 10 mm. The inferior vena cava and suprahepatic vessels were normal. The pancreas, spleen and kidneys were all normal. There were no ascites, however bilateral pleural effusion was detected.

A possible diagnosis of HELLP was made and supportive care for correction of coagulation disorder with fresh frozen plasma (FFP) and corticosteroids were administered. Because of deterioration in her mental state in conjunction with an increased bilirubin level and international normalized ratio (INR), the pregnancy was terminated. Vaginal delivery was not possible because of the patient's decreased mental state so a cesarean section was performed. The fetus was delivered and transferred to NICU but expired because of immaturity. At laparotomy, approximately one liter of ascitic fluid was noted in the abdomen and the liver had multiple malignant appearing mass lesions, which were biopsied with wedge resection. Pathologic evaluation showed sheaths of malignant hepatocytes typical of HCC (Figure 1).

After delivery the patient experienced progressive loss of conscious along with multi-organ failure and unfortunately died after a few days.

DISCUSSION

HCC during pregnancy is very rare and only 48 cases have been reported since Roddie's first report in 1957 until 2010 according to a PubMed literature review.⁶

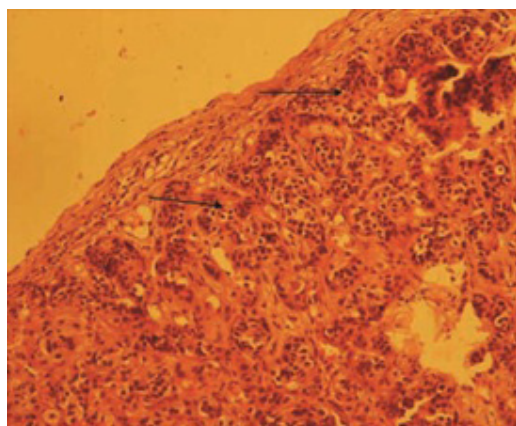


Fig.1: Surgical specimen of the liver showed pleomorphic appearances that confirmed hepatocellular carcinoma (HCC) (arrows).

We report this case who had unusual presentations. The incidence of HCC in pregnant women is about 1 per 100,000,⁵ of which most reside in Africa and Asia.²

According to the literature, the mean age of pregnant women with HCC was 28.9 ± 4.4 years after 1995. These women had fewer pregnancies, fewer signs and symptoms, and higher survival rates compared to women diagnosed before 1995 who were older (31.4 ± 7.2 years), diagnosed late in pregnancy and many of whom received no curative treatment.³

Choi et al.³ have shown that in the African or Asian race, particularly among the Chinese, HBV and OCPs are the main etiologies for HCC during pregnancy.⁷ Our case had negative HBsAg, HBcAb, and HCV Ab levels and had no past history of OCP consumption.

Our case was 41 years old and diagnosis was made in during the fourth pregnancy.

The risk of HCC increases with parity⁴ as shown in the present case but is very low in those who are HBsAg non-carriers, with an incidence of 0.55 per 100,000 in women reported by Fwuet al.⁸

HCC is rare during pregnancy because of the lower incidence of HCC in women during the reproductive years and infertility that is due to cirrhosis.² Pregnancy may have an adverse effect on the progression of HCC because of the effects of estrogen viral hepatitis carcinogenesis,⁹ however

some authors disagree.² Late menopause, early menarche, OCPs and multiparity have been reported as risk factors for HCC, again suggestive of the negative impact of pregnancy on HCC.¹⁰ Estrogen can increase hepatocyte mitosis, hypervascularity, free radicals, reactivate HBV and decrease humoral immunity.^{11,12}

HCC is asymptomatic in its early stages during pregnancy but right upper quadrant pain or the presence of a mass, weight loss and hepatomegaly have been the most frequent presentations, however our case presented with nausea and vomiting and abnormal liver enzymes which have been rare in reported cases (each, 6.4% in the literature).³

Our patient had hemolytic microangiopathic anemia, which was not found in previous cases and had no history of weight loss. In addition, a family history of HCC was only found in 8% of cases³, which again was present in our case.

In our case, the AFP level was about 90ng/ml and unusual for HCC. Maternal AFP levels are used to screen for Down Syndrome or neural tube defects and it has been suggested that elevated AFP in a pregnant patient with a normal fetus is indicative of maternal disease, particularly HCC.¹ However AFP screening for HCC lacks sensitivity because it depends on maternal weight, age, diabetes and ethnicity. Previous studies have shown that 10% of pregnant women can have HCC with normal AFP levels and 55.3% have AFP levels less than 400 ng/ml, thus AFP alone has a high positive predictive value.³ CA 125, which is primarily used for ovarian cancer could be rarely elevated in HCC; elevations more than 1000ng/dl as seen in our patient have been previously reported.¹³

Other laboratory abnormalities that include hyperbilirubinemia, prolonged of prothrombin time and hypoalbuminemia, which were present in this case have been reported in less than 10% of previous studies.³

Our patient also had multiple lesions and her Barcelona Clinic Liver Cancer Staging System (BLCL staging) was stage 4. Choi et al.³ reported 33.3% of their patients had multiple lesions and 21.7% were BLCL stage 4.

Liver resection is the best management if possible but in cases such as ours termination of pregnancy as soon as possible is recommended.^{1,3} Improvement in the surgery methods would result in a three-year survival rate of 62.5% and the potential for uneventful pregnancy in such cases.³

HCC during pregnancy has a poor outcome and 20% of patients have distant metastasis at presentation according to previous reports, however fibrolamellar HCC has a better prognosis. Delivery was by cesarean section in 44.82% and live births were present in only 58.7% cases.³ Unfortunately our patient and her fetus both died soon after diagnosis and cesarean section.

As conclusion, malignancies should be carefully approached and considered as differential diagnoses in pregnant women. Those with a family history of cancer should be more closely worked up, even if they present with unusual manifestations.

CONFLICT OF INTEREST

The authors declare no conflict of interest related to this work.

REFERENCES

1. Cobey FC, Salem RR. A review of liver masses in pregnancy and a proposed algorithm for their diagnosis and management. *Am J Surg* 2004;**187**:181-91.
2. Lau W, Leung W, Ho S, Lam S, Li C, Johnson P, et al. Hepatocellular carcinoma during pregnancy and its comparison with other pregnancy-associated malignancies. *Cancer* 1995;**75**:2669-76.
3. Choi KK, Hong YJ, Choi SB, Park YN, Choi JS, Lee WJ, et al. Hepatocellular carcinoma during pregnancy: is hepatocellular carcinoma more aggressive in pregnant patients? *J Hepatobiliary Pancreat Sci* 2011;**18**:422-31.
4. Jonas MM. Hepatitis B and pregnancy: an underestimated issue. *Liver Int* 2009;**29**Suppl 1:133-9
5. El-Serag HB. Hepatocellular Carcinoma. *N Engl J Med* 2011;**365**:1118-27.
6. Roddie TW. Haemorrhage from primary carcinoma of the liver complicating pregnancy. *Br Med J* 1957;**1**:31.
7. Lee HS, Lee JS, Woo GH, Yoon JH, Kim CY. Recurrent hepatocellular carcinoma after spontaneous regression. *J Gastroenterol* 2000;**35**:552-6.
8. Fwu CW, Chien YC, Kirk GD, Nelson KE, You SL, Kuo HS, et al. Hepatitis B virus infection and hepatocellular carcinoma among parous Taiwanese women: nationwide cohort study. *J Natl Cancer Inst* 2009;**101**:1019-27.
9. Alvarez de la Rosa M, Nicolás-Pérez D, Muñiz-Montes JR, Trujillo-Carrillo JL. Evolution and management of a hepatocellular carcinoma during pregnancy. *J Obstet Gynaecol Res* 2006 ;**32**:437-9.
10. Mucci LA, Kuper HE, Tamimi R, Laggiou P, Spanos E, Trichopoulos D. Age at menarche and age at menopause in relation to hepatocellular carcinoma in women. *BJOG* 2001;**108**:291-4.
11. De Maria N, Manno M, Villa E. Sex hormones and liver cancer. *Mol Cell Endocrinol* 2002;**193**:59-63.
12. Garko SB, David O, Mohammed T, Isah M, Bakari A, Oguntayo A, et al. Hepatocellular carcinoma in pregnancy. *Ann Afr Med* 2009;**8**:284-6.
13. Perkins GL, Slater ED, Sanders GK, Prichard JG. Serum tumor markers. *Am Fam Physician* 2003;**68**:1075-82.